EUROPEAN UROLOGY 87 (2025) 697–716

available at www.sciencedirect.com
journal homepage: www.europeanurology.com

European Association of Urology

EAU Guidelines – Editor's choice

European Association of Urology Guidelines on Upper Urinary Tract Urothelial Carcinoma: Summary of the 2025 Update

Alexandra Masson-Lecomte[a,*], *Alison Birtle*[b,c,d], *Benjamin Pradere*[e], *Otakar Capoun*[f], *Eva Compérat*[g], *José L. Domínguez-Escrig*[h], *Fredrik Liedberg*[i,j], *Lydia Makaroff*[k,l], *Paramananthan Mariappan*[m], *Marco Moschini*[n], *Bhavan P. Rai*[o], *Bas W.G. van Rhijn*[p], *Shahrokh F. Shariat*[q], *Emma J. Smith*[r], *Jeremy Y.C. Teoh*[s], *Viktor Soukup*[f], *Robert Wood*[t], *Evanguelos N. Xylinas*[u], *Francesco Soria*[v], *Thomas Seisen*[w,x], *Paolo Gontero*[v]

[a] *Department of Urology, St. Louis Hospital, AP-HP, Université de Paris, Paris, France;* [b] *Rosemere Cancer Centre, Lancashire Teaching Hospitals NHS Foundation Trust, Preston, UK;* [c] *University of Manchester, Manchester, UK;* [d] *University of Central Lancashire, Preston, UK;* [e] *Department of Urology, UROSUD, La Croix Du Sud Hospital, Quint Fonsegrives, France;* [f] *Department of Urology, General University Hospital and 1st Faculty of Medicine, Charles University Praha, Prague, Czechia;* [g] *Department of Pathology, Medical University of Vienna, Vienna, Austria;* [h] *Department of Urology, Fundación Instituto Valenciano de Oncología, Valencia, Spain;* [i] *Institution of Translational Medicine, Lund University, Malmö, Sweden;* [j] *Department of Urology, Skåne University Hospital, Malmö, Sweden;* [k] *Fight Bladder Cancer, Chinnor, UK;* [l] *World Bladder Cancer Patient Coalition, Brussels, Belgium;* [m] *Edinburgh Bladder Cancer Surgery, University of Edinburgh, Western General Hospital, Edinburgh, UK;* [n] *Division of Experimental Oncology/Unit of Urology, Urological Research Institute, IRCCS San Raffaele Scientific Institute, Milan, Italy;* [o] *Department of Urology, Freeman Hospital, Newcastle upon Tyne Hospitals NHS Foundation Trust, Newcastle upon Tyne, UK;* [p] *Department of Surgical Oncology (Urology), Netherlands Cancer Institute-Antoni van Leeuwenhoek Hospital, Amsterdam, The Netherlands;* [q] *Department of Urology, Comprehensive Cancer Center, Vienna General Hospital, Medical University of Vienna, Vienna, Austria;* [r] *Guidelines Office, European Association of Urology, Arnhem, The Netherlands;* [s] *S.H. Ho Urology Centre, Department of Surgery, Faculty of Medicine, Chinese University of Hong Kong, Hong Kong, China;* [t] *Patient representative, European Association of Urology, Arnhem, The Netherlands;* [u] *Department of Urology, Bichat-Claude Bernard Hospital, AP-HP, Université de Paris, Paris, France;* [v] *Department of Urology, Città della Salute e della Scienza, University of Torino School of Medicine, Torino, Italy;* [w] *GRC 5 Predictive Onco-Uro, Sorbonne University, Paris, France;* [x] *Department of Urology, Pitie-Salpetriere Hospital, AP-HP, Paris, France*

Article info

Article history:
Accepted February 26, 2025

Keywords:
(Neo)adjuvant therapy
Chemotherapy
Genetic screening
Immunotherapy
Management
Prognostic factors
Renal pelvis

Abstract

Background and objective: We present a summary of the 2025 update for the European Association of Urology (EAU) guidelines for upper urinary tract urothelial carcinoma (UTUC). The aim is to provide practical recommendations on the clinical management of UTUC with a focus on diagnosis, treatment, and follow-up.

Methods: For the 2025 guidelines on UTUC, new and relevant evidence was identified, collated, and appraised via a structured assessment of the literature. Databases searched included Medline, EMBASE, and the Cochrane Libraries. Recommendations within the guidelines were developed by the panel to prioritise clinically important care decisions. The strength of each recommendation was determined according to a balance between desirable and undesirable consequences of alternative management strategies, the quality of the evidence (including the certainty of estimates), and the nature and variability of patient values and preferences.

* Corresponding author. Department of Urology, St. Louis Hospital, AP-HP, Université de Paris, Paris, France.
E-mail address: alexandra.massonlecomte@aphp.fr (A. Masson-Lecomte).

https://doi.org/10.1016/j.eururo.2025.02.023
0302-2838//© 2025 European Association of Urology. Published by Elsevier B.V. All rights are reserved, including those for text and data mining, AI training, and similar technologies.

Surgery
Ureter
Urothelial carcinoma

Please visit www.eu-acme.org/europeanurology to answer questions on-line. The EU-ACME credits will then be attributed automatically.

Key findings and limitations: Key recommendations emphasise the importance of thorough diagnosis, treatment, and follow-up for patients with UTUC. The guidelines stress the importance of appropriate treatment taking into account patient values and preferences. Key updates in the 2025 UTUC guidelines include: significant changes to the recommendations for UTUC diagnosis; complete revision of the sections addressing risk stratification, ureteroscopy, and the surgical approach for radical nephroureterectomy; addition of four new recommendations, two related to kidney-sparing management of localised low-risk UTUC and a further two related to management of high-risk non-metastatic UTUC; a review and adaptation of recommendation for UTUC follow-up; and addition of a new section addressing quality indicators for UTUC management.
Conclusions and clinical implications: This overview of the 2025 EAU guidelines on UTUC offers valuable insights into risk factors, diagnosis, classification, treatment, and follow-up for UTUC. The guidelines contain information on the management of individual patients according to the current best evidence and are designed for effective integration in clinical practice.

© 2025 European Association of Urology. Published by Elsevier B.V. All rights are reserved, including those for text and data mining, AI training, and similar technologies.

1. Introduction

We present a summary of the 2025 update for the European Association of Urology (EAU) guidelines on localised and metastatic upper urinary tract urothelial carcinoma (UTUC). Separate EAU guidelines are available addressing non–muscle-invasive bladder cancer (NMIBC) [1], muscle-invasive and metastatic bladder cancer (MIBC) [2], and primary urethral carcinoma [3].

It must be emphasised that although clinical guidelines present the best evidence available to the experts, following guideline recommendations will not necessarily result in the best outcome. Guidelines can never replace clinical expertise when making treatment decisions for individual patients, but can help in focusing decisions that also take the personal values, preferences, and individual circumstances of patients into account. Guidelines are not mandates and do not purport to be a legal standard of care.

2. Methods

For the 2025 UTUC guidelines, new and relevant evidence has been identified, collated, and appraised via a structured assessment of the literature. A broad and comprehensive scoping exercise covering all areas of the UTUC guidelines was performed. A detailed search strategy is available online (https://uroweb.org/guidelines/upper-urinary-tract-urothelial-cell-carcinoma/publications-appendices).

Recommendations included in the guidelines were developed by the panel to prioritise clinically important care decisions. The strength of each recommendation is determined by the balance between desirable and undesirable consequences of alternative management strategies, the quality of the evidence (including certainty of estimates), and the nature and variability of patient values and preferences. Strong recommendations typically indicate a high degree of evidence quality and/or a favourable balance of benefits/harms and patient preferences. Weak recommendations typically indicate lower quality evidence and/or an equivocal balance between benefits and harms, and uncertainty or variability in patient preferences [4].

3. Guidelines

3.1. *Epidemiology, aetiology and pathology*

3.1.1. *Epidemiology*

Urothelial carcinoma (UC) is the second most common urological malignancy in developed countries [5]. UCs can be localised in the lower (bladder and urethra) and/or the upper (pyelocaliceal cavities and ureter) urinary tract. Bladder cancer (BC) accounts for 90–95% of UCs. UTUC accounts for only 5–10% of UCs with an estimated annual incidence in Western countries of almost two cases per 100 000 inhabitants [1]. Peak UTUC incidence occurs in the group aged 70–90 yr, and UTUC is twice as common among men [6].

Approximately two-thirds of patients who present with UTUC have muscle-invasive disease at diagnosis, in comparison to 15–25% of patients diagnosed with de novo BC [7]. Approximately 9% of patients present with metastases [8]. Concurrent BC is present in 17% of UTUC cases [9]; a history of BC is found in 41% of American men but only 4% of Chinese men with UTUC [10]. UTUC prevalence ranged from 7.5% to 25% among patients with high-risk NMIBC treated with intravesical bacillus Calmette-Guérin (BCG) [11–13] and from 3% to 5% among patients with MIBC treated with radical cystectomy [14].

Following treatment for UTUC, recurrence in the bladder occurs in 29% of UTUC cases, depending on patient-, tumour- and treatment-specific characteristics [15]. The recurrence rate in the contralateral upper tract is 2–5% [16].

3.1.2. *Risk factors*

3.1.2.1. Environmental risk factors. A number of environmental risk factors have been implicated in UTUC development [17,18]. With the exception of smoking and aristolochic acid, no strong evidence supports a causative role for these factors. Tobacco exposure increases the rela-

tive risk of developing UTUC by 2.5- to 7.0-fold [19–21]. Aristolochic acid has negative effects on the urinary system via irreversible injury to renal proximal tubules that results in chronic tubulointerstitial disease, while its mutagenic properties can lead to UTUC [22–24]. However, it is estimated that less than 10% of individuals exposed to aristolochic acid develop UTUC [24].

3.1.2.2. Genetic risk factors. Lynch syndrome is characterised by a predisposition to early-onset colorectal cancer and several extracolonic malignancies related to pathogenic germline mutations in an allele of one the mismatch repair (MMR) genes *MLH1*, *MSH2*, *MSH6*, or *PMS2*. After colorectal and endometrial cancers, UTUC is the third most common malignancy in the Lynch syndrome spectrum [25]. Identification of Lynch syndrome–related UTUC has important clinical implications for both the patient and their relatives given the high risk of developing multiple different malignancies in carriers and the strong hereditary predisposition of this condition. Germline mutations in MMR genes can be found in 1–3% of patients with UTUC [26]. From a genetic perspective, the majority of tumours develop in *MSH2* and *MSH6* mutation carriers [27]. From a clinical perspective, the Amsterdam II criteria are predominantly used to identify families at higher risk of Lynch syndrome [28]. A UTUC-specific study has suggested that age <60 yr at initial diagnosis and a personal history of any other Lynch-related malignancy could be associated with higher risk of Lynch syndrome in these patients [29]. A simplified screening tool for UTUC patients has been proposed and is presented in Fig. 1.

Using this simplified screening tool, the proportion of UTUC patients with a suspicion of Lynch-related disease could be more than 20% [30]. Importantly, patients with UTUC who are identified as being at high risk of Lynch syndrome on the basis of clinical criteria should undergo germline DNA sequencing and family counselling (Table 1) [31,32]. However, given the limited diagnostic performance of clinical criteria, UTUC tumour specimens from patients with no suspicion of genetic predisposing factors could be tested for microsatellite instability (MSI) via polymerase chain reaction or for deficient MMR using immunochemistry [33]. An MSI or deficient MMR phenotype can be identified in 1.7–46% or 2.4–57% of cases, respectively [33]. As for any clinical suspicion of hereditary UTUC, those with a positive test should also undergo germline DNA sequencing and family counselling [26,34–37].

3.1.3. Histology and classification

Tumours in the upper urinary tract are almost always UCs, and pure nonurothelial histology is rare [38,39]. However, histological subtypes are present in approximately 25% of

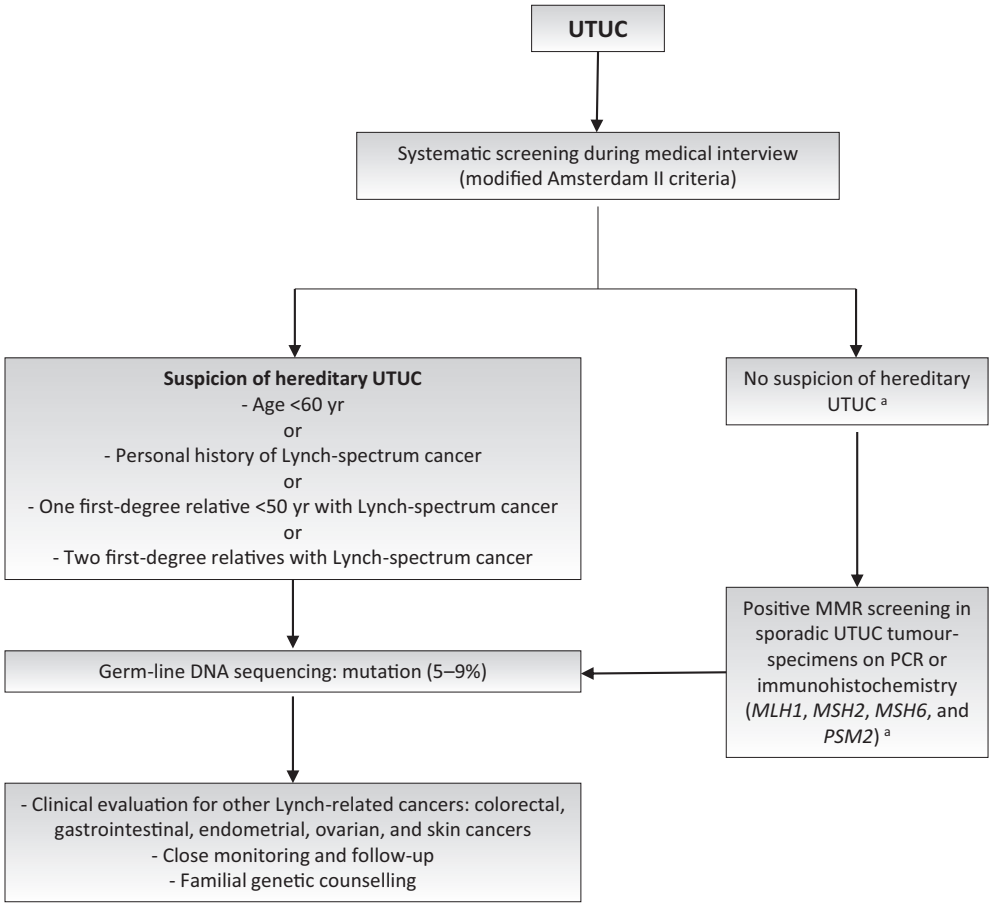

Fig. 1 – Selection of patients with UTUC for Lynch syndrome screening during the first medical interview. MMR = mismatch repair; PCR = polymerase chain reaction; UTUC = upper urinary tract urothelial carcinoma. [a] These patients may benefit from MMR deficiency screening via PCR or immunohistochemistry. A positive result should prompt subsequent testing for germline DNA sequencing mutations in MMR genes (*MLH1*, *MSH2*, *MSH6*, and *PSM2*).

Table 1 – Recommendations for UTUC epidemiology, aetiology, and histology

Recommendation	Strengthrating
Evaluate patient and family history to screen patients for Lynch syndrome using the modified Amsterdam II criteria.	Strong
Perform germline DNA sequencing in patients with a clinical suspicion of hereditary UTUC.	Strong
Offer testing for mismatch repair proteins or microsatellite instability in patients without a clinical suspicion of hereditary UTUC.	Weak

UTUC = upper urinary tract urothelial carcinoma.

UTUCs [40,41]. UTUCs with different subtypes are of high grade and have worse prognosis than pure UC [41–43]. Collecting duct carcinomas, which may seem to share similar characteristics with UCs, have a unique transcriptomic signature and are considered as renal tumours [44].

3.1.4. Molecular background of UTUCs

A number of molecular classification studies have been able to demonstrate genetically distinct UTUC groups via evaluation of DNA, RNA, and protein expression. The most common genomic alterations are in *FGFR3*, chromatin remodelling genes (*KMT2D* and *KDM6A*), *TP53*/*MDM2*, and other typical tumour suppressor genes/oncogenes such as *CDKN2A* and *RAS* [45].

3.2. Classification and staging systems

3.2.1. Classification

The classification and morphology of UTUC and BC are similar [1]. However, because sample acquisition may be inadequate, it is often difficult to distinguish between noninvasive papillary tumours [46], flat lesions (carcinoma in situ [CIS]), and invasive carcinoma in biopsies. Therefore, histological grade is often used for clinical decision-making, as it is strongly associated with pathological stage [47].

3.2.2. TNM staging

The TNM classification is shown in Table 2 [48]. The regional lymph nodes (LNs) are the hilar and retroperitoneal nodes, as well as the pelvic nodes for the mid-ureter and distal ureter. Laterality does not affect nodal classification.

3.2.3. Tumour grade

In 2004 and 2022, the World Health Organisation (WHO) published a new UC histological classification with different patient stratification between individual categories in comparison to the older 1973 WHO classification [49–51]. The EAU guidelines are still based on both the 1973 and 2004/2016 WHO classifications since most of the published studies used the 1973 classification [46].

3.3. Diagnosis

3.3.1. Symptoms

The diagnosis of UTUC may be incidental or symptom-related. The most common symptom is haematuria [52]. Flank pain, due to clot or tumour tissue obstruction, can occur in 20–32% of cases [52]. Preoperative symptoms at diagnosis are associated with worse prognosis [53].

Table 2 – TNM 2016 classification for upper tract urothelial cell carcinoma [48]

T: Primary tumour
TX Primary tumour cannot be assessed
T0 No evidence of primary tumour
Ta Noninvasive papillary carcinoma
Tis Carcinoma in situ
T1 Tumour invades subepithelial connective tissue
T2 Tumour invades muscularis
T3 (Renal pelvis) Tumour invades beyond muscularis into peripelvic fat or renal parenchyma (Ureter) Tumour invades beyond muscularis into periureteric fat
T4 Tumour invades adjacent organs or through the kidney into perinephric fat
N: Regional lymph nodes
NX Regional lymph nodes cannot be assessed
N0 No regional lymph node metastasis
N1 Metastasis in a single lymph node 2 cm or less in the greatest dimension
N2 Metastasis in a single lymph node more than 2 cm, or multiple lymph nodes
M: Distant metastasis
M0 No distant metastasis
M1 Distant metastasis

3.3.2. Imaging

3.3.2.1. Computed tomography. Computed tomography (CT) urography has the highest diagnostic accuracy among the imaging techniques available [54]. A meta-analysis of 13 studies comprising 1233 patients revealed pooled CT urography sensitivity of 92% (95% confidence interval [CI] 0.85–0.96) and pooled specificity of 95% (95% CI 0.88–0.98) for UTUC detection [55]. Rapid acquisition of thin sections yields high-resolution images of both upper urinary tracts that can be viewed in multiple planes to assist with diagnosis without loss of resolution. The presence of enlarged LNs on CT is highly predictive of metastases in UTUC [56,57]. The risk of thoracic metastases is extremely low in low-risk UTUC.

3.3.2.2. Magnetic resonance urography. Magnetic resonance (MR) urography is indicated in patients who cannot undergo CT urography, usually when radiation or iodinated contrast media are contraindicated [58]. The sensitivity of MR urography for tumours <2 cm is 75% after contrast injection [58].

3.3.2.3. ^{18}F-Fluorodeoxglucose positron emission tomography/CT. A retrospective multicentre study on the use of ^{18}F-fluorodeoxglucose (FDG) positron emission tomography (PET)/CT for detection of nodal metastasis in 117 surgically treated UTUC cases revealed promising sensitivity of 82% and specificity of 84%. Suspicious LNs on FDG-PET/CT were associated with worse recurrence-free survival (RFS) [59]. These results warrant further validation and comparison with MR and CT. FDG-PET can also be used to assess nodal and distant metastases in patients unfit for iodinated contrast media because of renal impairment and/or allergy.

3.3.3. Cystoscopy

Urethrocystoscopy is an integral part of the UTUC workup to rule out concomitant BC [9,60].

3.3.4. Cytology and urinary markers

Voided urine cytology may indicate high-grade UTUC when bladder cystoscopy is normal, and in the absence of CIS in the bladder and prostatic urethra [1,61]. Voided urine cytology is less sensitive for UTUC than cytology for urine selectively obtained from the affected upper tract [62]. In a recent study, barbotage cytology detected up to 91% of cancers [63]. In a systematic review of 25 studies on cytology and urinary markers, cytology and fluorescence in situ hybridisation (FISH) were most commonly used [64]. FISH, multiplex urinary markers, and cytology could be helpful as ancillary tools for detecting UTUC; however, further confirmation in well-designed prospective comparative trials is needed.

3.3.5. Diagnostic ureteroscopy

Flexible ureteroscopy (URS) is used if necessary to confirm the diagnosis of UTUC via visualisation of the ureter, renal pelvis, and collecting system, with biopsy of suspicious lesions. URS is also essential for meticulous tumour mapping before considering kidney-sparing options for UTUC. The presence, appearance, multifocality, and size of the tumour can be estimated during URS. In addition, URS biopsies can determine tumour grade in more than 90% of cases with a low false-negative rate, regardless of sample size [65]. However, undergrading and understaging leading to inaccurate risk stratification can occur with diagnostic URS biopsy when compared to nephroureterectomy specimens [47,66,67].

URS also facilitates selective ureteral sampling for cytology [68]. Stage assessment using URS biopsy can be inaccurate, so combining URS biopsy grade, imaging findings, and urinary cytology may help in deciding between radical nephroureterectomy (RNU) and a kidney-sparing approach [68,69]. In a meta-analysis comparing URS versus no URS before RNU, eight out of 12 studies found an increase in the risk of intravesical recurrence for those undergoing URS [70]. Performing a biopsy during URS was also identified as a risk factor for intravesical recurrence [70]. A second systematic review of 16 studies showed that URS alone was not significantly related to intravesical recurrence, whereas URS with a biopsy significantly increased the risk of subsequent intravesical recurrence, albeit without an impact on recurrences outside the urinary tract and overall survival (OS) [71].

Technical developments for flexible ureteroscopes and the use of novel imaging techniques may improve the visualisation and diagnosis of flat lesions [72].

Table 3 – Recommendations for the diagnosis of UTUC

Recommendation	Strengthrating
Perform urethrocystoscopy to rule out bladder tumour.	Strong
Perform voided urinary cytology in any case with suspicion of upper tract tumour.	Weak
Perform CT, or MRI if CT is contraindicated, with urography for diagnosis and staging of all upper tract tumours.	Strong
Perform chest CT for cases with high-risk tumours.	Strong
^{18}F-Fluorodeoxglucose PET/CT may be used to rule out metastases in high-risk disease.	Weak
Use diagnostic URS if imaging and voided urine cytology are not sufficient for diagnosis and/or risk stratification of patients suspected to have UTUC.	Strong
Test for FGFR 2/3 alterations at initial diagnosis in the metastatic setting.	Strong

CT = computed tomography; MRI = magnetic resonance imaging; PET = positron emission tomography; URS = ureteroscopy; UTUC = upper urinary tract urothelial carcinoma.

3.3.6. Molecular testing

Next-generation sequencing should be used to test for *FGFR2/3* alterations in the metastatic setting (see Section 3.5.3.2.2), preferably in tissue from an invasive part of the tumour or metastatic site (Table 3) [73,74].

3.4. Risk stratification

3.4.1. Factors for clinical decision-making

The main prognostic factor in UTUC is pathological tumour stage [68,75]. UTUCs that invade the muscle have poor prognosis. In a large UTUC series from the Netherlands, the 5-yr cancer-specific survival (CSS) rate was 86% for non–muscle-invasive tumours, 70% for muscle-invasive organ-confined tumours, and 44% for locally advanced tumours [76]. A contemporary Surveillance, Epidemiology and End Results analysis of RNU for high-risk disease showed 5-yr CSS rates of 86% for T1 N0, 77% for T2 N0, 63% for T3 N0, and 39% for T4 N0/T_{any} N1–2 disease [77].

3.4.1.1. Tumour grading. Tumour grade reflects tumour aggressiveness and could serve as a surrogate predictor of disease progression. It has been shown that a higher tumour grade is associated with high rates of disease recurrence and worse CSS following initial RNU [7,78]. Histological grade is one of the most important surrogate markers for pathological stage in UTUC. Multiple studies have established a strong correlation between high-grade tumours and advanced pathological stages, particularly muscle-invasive disease (≥pT2). Similarly, another study found that tumour grade is a reliable predictor of non–organ-confined disease, showing that high-grade tumours have a significantly higher likelihood of metastasis and are an independent predictor of CSS and RFS following RNU [7]. Consequently, histological grade serves as a critical factor in guiding clinical decisions, particularly when imaging and biopsy results are insufficient for accurate staging.

3.4.1.2. Histological subtypes. Histological UC subtypes are associated with worse CSS and OS [41]. The subtypes most studied are squamous UC [79], sarcomatoid UC [42], and micropapillary UC [42], all of which are consistently associated with locally advanced disease and worse outcomes [80]. For patients harbouring histological UC subtypes, RNU should be recommended during the shared-decision making process owing to the higher risk of disease progression.

3.4.1.3. Local invasion on CT. CT urography remains the main tool for initial diagnosis of UTUC. Several studies have demonstrated that CT urography provides high diagnostic accuracy for UTUC detection [55]. A meta-analysis revealed that CT urography has sensitivity of 92% and specificity of

95% for identifying muscle-invasive disease [55]. Moreover, another study demonstrated that CT can accurately predict pathological stage, particularly when identifying peripelvic fat invasion and non–organ-confined tumour (NOCT), which are critical indicators of advanced UTUC [81]. While biopsies may sometimes understage UTUC because of limited sample size, CT imaging offers a noninvasive and comprehensive assessment of tumour invasion, especially in cases of large or deeply invasive lesions [81]. For local staging, CT urography can also provide additional information on local invasion into the renal parenchyma, renal pelvis, and periureteric tissue [82]. After adjusting for tumour size and hydronephrosis, local invasion on CT remains a significant risk factor for NOCT [82]. These findings indicate that CT urography is a valuable modality in the preoperative assessment of UTUC and in guiding appropriate treatment strategies according to tumour stage, particularly NOCT. However, the ability of CT to differentiate Ta, T1, and T2 tumours is low.

3.4.1.4. Multifocality. It has been reported that approximately 7–42% of UTUC cases harbour multifocal tumours [83–85]. Patients with multifocal tumours are more likely to have advanced-stage disease and worse prognosis despite treatment with RNU [83–85]. However, multifocal tumours can also be present in otherwise low-grade UTUC. It is important to note that the definition of multifocality varies among studies. Some studies consider the number of lesions [84], while others focus on tumour location (ie, both renal pelvis and ureter) [83,85,86]. Therefore, tumour multifocality should not be used as the sole factor for risk stratification.

3.4.1.5. Hydroureteronephrosis. Hydroureteronephrosis has been linked to advanced disease and poor prognosis in patients treated with RNU. A meta-analysis of 22 studies involving 7542 patients found that preoperative hydroureteronephrosis was significantly associated with ureteral tumour location, advanced tumour stage, and LN metastasis [87]. In addition, preoperative hydroureteronephrosis was independently associated with worse OS, CSS, and disease-free survival (DFS) [87]. However, as for multifocality, it is important to note that the definition of hydronephrosis varies among studies, with heterogeneity and potential confounding factors. Taking into consideration that some otherwise low-risk tumours might exhibit some degree of upper tract dilation, the presence of signs of obstruction should be considered alongside other high-risk factors (Fig. 2).

3.4.1.6. Tumour size. Greater tumour size is linked to a higher risk of muscle-invasive disease and NOCT in both ureteral and renal pelvis UTUC cases [88]. A meta-analysis of 32 292 patients confirmed that larger tumour size is significantly associated with worse OS, CSS, and DFS, as well as intravesical recurrence [88]. In renal pelvis UTUC, for which median tumour size ranges from 3.5 to 4.0 cm, each 1-cm increment in tumour size increases the risk of harbouring muscle-invasive disease at RNU by 1.25-fold [89]. A multi-institutional study involving 932 patients suggested that a tumour size of 2 cm serves as the optimal threshold for identifying high-risk disease (>pT2 UTUC) [90]. However, measurement of tumour size lacks standardisation, leading to interassessor variability. Overall, like tumour multifocality and hydroureteronephrosis, tumour size assessment suffers from heterogeneity and potential confounding factors. Tumour size should be considered as a continuous variable associated with stage, but is insufficient by itself for precise risk stratification.

3.4.1.7. Risk stratification for clinical decision-making. The factors to consider for risk stratification (Table 4) and the weight given to each factor are presented in Fig. 2. Grade remains the most important surrogate factor reflecting

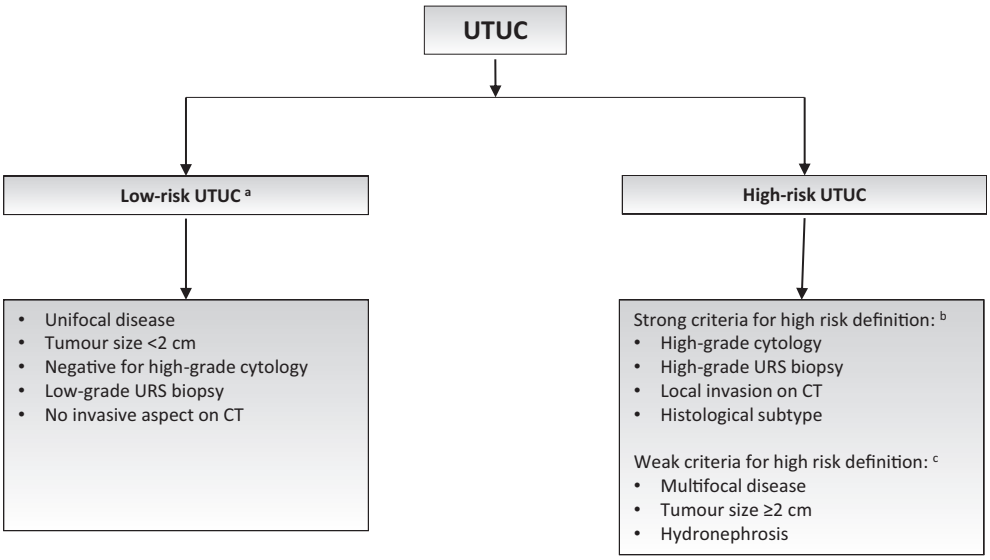

Fig. 2 – Stratification of nonmetastatic UTUC according to the risk of progression to >pT2/non–organ-confined disease. CT = computed tomography; URS = ureteroscopy; UTUC = upper urinary tract urothelial carcinoma. [a] All of these factors need to be present. [b] Any of these factors needs to be present. [c] In the presence of low-grade tumour, these factors are not strong predictors of invasive disease.

Table 4 – Recommendation for risk stratification of upper urinary tract urothelial carcinoma

Recommendation	Strength rating
Use prognostic factors to risk-stratify patients for therapeutic guidance.	Strong

tumour stage and aggressiveness. The level of evidence for tumour size, multifocality, and hydronephrosis as individual surrogates for high risk of progression remains low. Therefore, for cases with low-grade disease associated with these factors, a shared decision-making process with the patient is important to agree on the therapeutic strategy (kidney-sparing option or RNU).

3.4.2. *Bladder recurrence*

A meta-analysis of available data identified significant predictors of bladder recurrence after RNU [15]. Three categories of predictors of higher risk of bladder recurrence were proposed:

1. Patient-specific factors: male sex, previous BC, smoking, and preoperative chronic kidney disease.
2. Tumour-specific factors: positive preoperative urinary cytology, tumour grade, ureteral location, multifocality, tumour diameter, invasive pT stage, and necrosis [91,92].

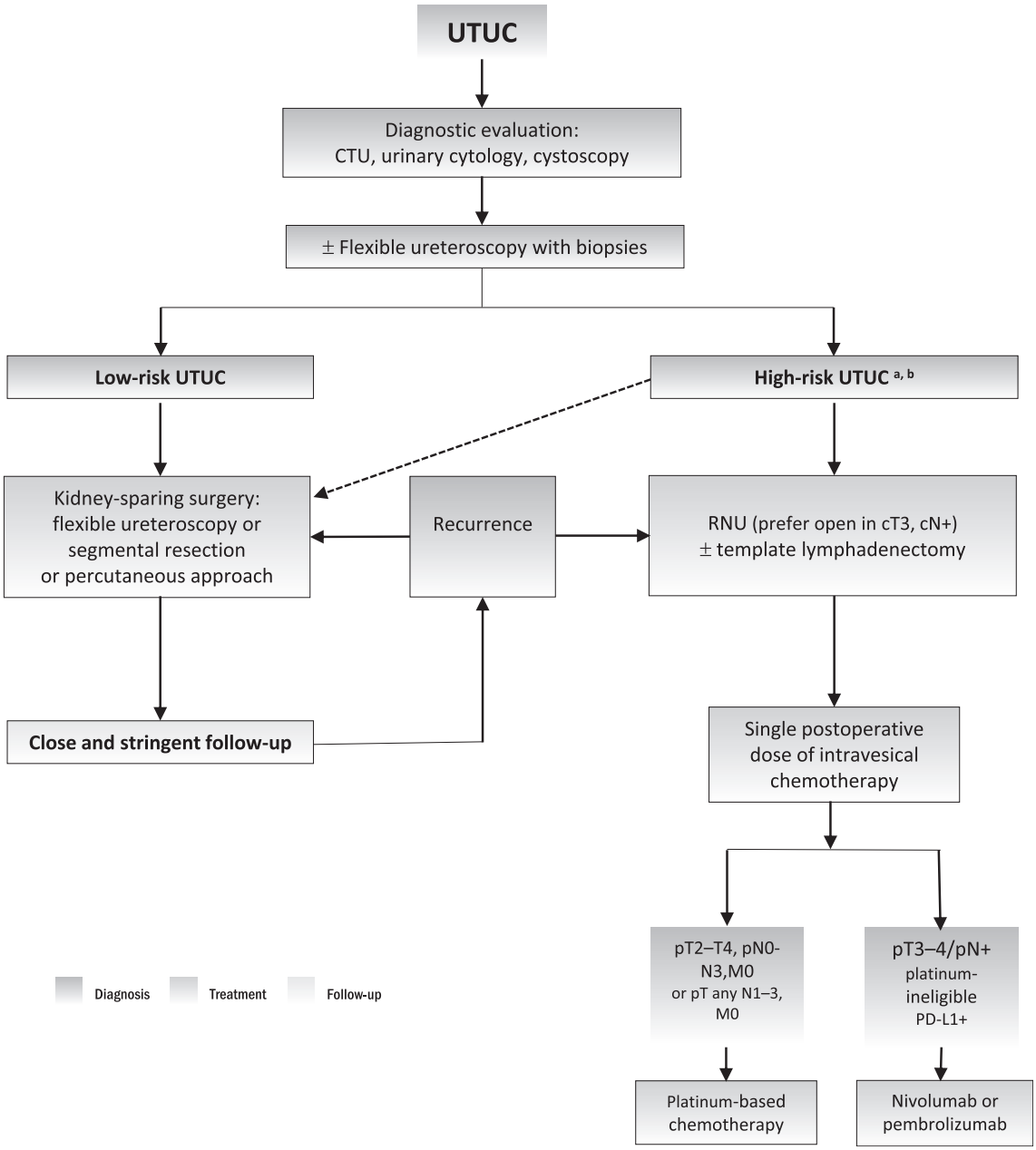

Fig. 3 – Proposed flowchart for the management of UTUC. CTU = computed tomography urography; RNU = radical nephroureterectomy; UTUC = upper urinary tract urothelial carcinoma. [a] In patients with a solitary kidney, consider a more conservative approach. [b] In patients with low-grade disease without invasive features, consider a more conservative approach.

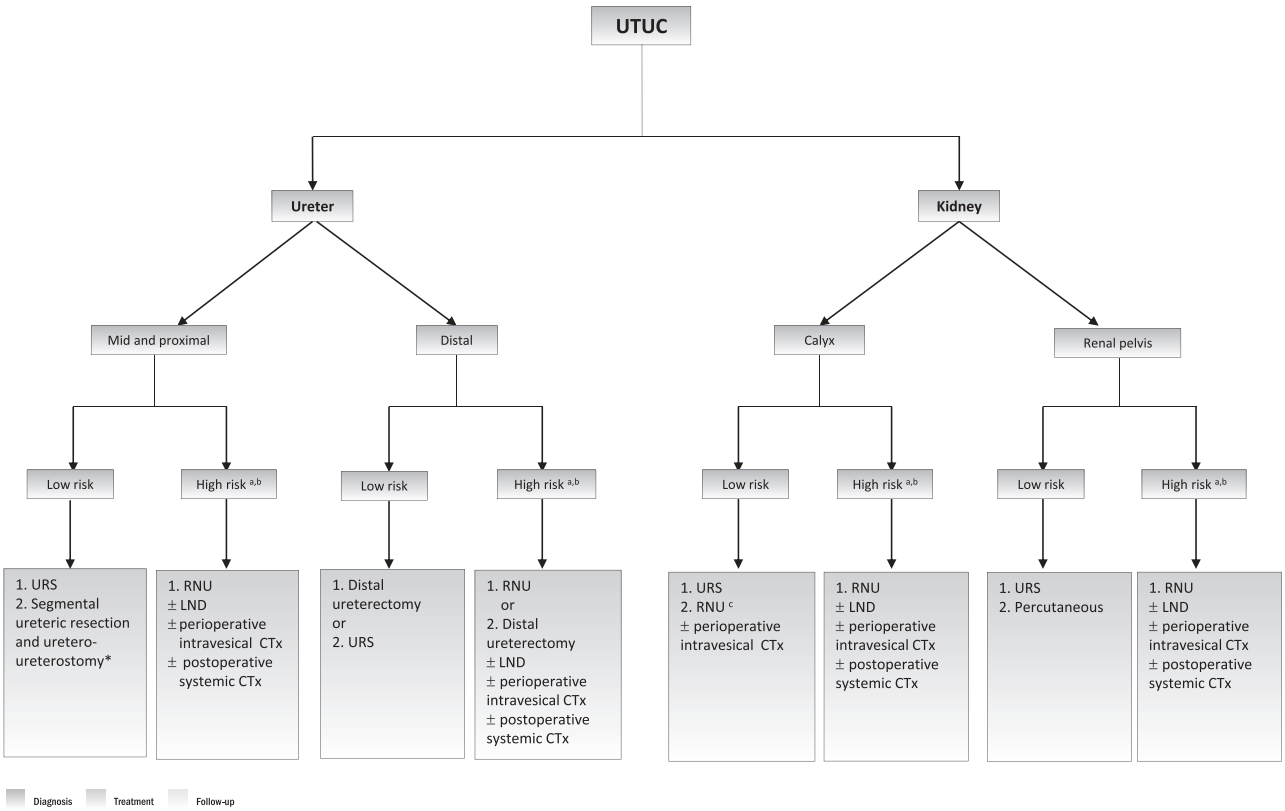

Fig. 4 – Surgical treatment according to location and risk status. 1 = first treatment option; 2 = secondary treatment option. CTx = chemotherapy; LND = lymph node dissection; RNU = radical nephroureterectomy; URS = ureteroscopy; UTUC = upper urinary tract urothelial carcinoma. [a] In patients with a solitary kidney, consider a more conservative approach. [b] In patients with low-grade disease without invasive features, consider a more conservative approach. [c] In cases not amendable to endoscopic management.

3. Treatment-specific factors: laparoscopic approach, extravesical bladder-cuff removal, and positive surgical margins.

In addition, the use of invasive diagnostic modalities, particularly URS with biopsy, has been associated with higher risk of developing bladder recurrence after RNU [93–95].

3.5. *Disease management*

All cases with a suspicion of UTUC on the basis of radiology, cystoscopy, and urine cytology should be discussed in a multidisciplinary team before diagnostic URS and initiation of treatment [96]. This is supported by population-based data revealing greater use of invasive diagnostic modalities in hospitals with lower case loads [95]. Disease management according to tumour location and risk status is outlined in Figs. 3 and 4.

3.5.1. *Low-risk disease*

3.5.1.1. General considerations for kidney-sparing surgery. Kidney-sparing surgery for low-risk UTUC reduces the morbidity associated with RNU (eg, loss of kidney function) without compromising oncological outcomes [97]. For low-risk cancers, kidney-sparing surgery is the preferred approach, as survival is similar to that after RNU [97,98]. This option should therefore be discussed for all low-risk cases, irrespective of the status of the contralateral kidney, in a shared-decision making process with the patient (Table 5).

Table 5 – Recommendations for kidney-sparing management of localised low-risk upper urinary tract urothelial carcinoma

Recommendation	Strengthrating
Offer kidney-sparing management as the primary treatment option to patients with low-risk tumours.	Strong
Discuss both endoscopic management and distal ureterectomy for low-risk tumours in the distal ureter on the basis of tumour characteristics in shared decision-making with the patient.	Strong
Perform second-look ureteroscopy within 8 wk after initial endoscopic management.	Weak

3.5.1.2. Ureteroscopy. Endoscopic ablation should be considered for patients with low-risk cancer [99,100]. A flexible ureteroscope is useful in the management of pelvicaliceal tumours [101]. The patient should be informed of the need for and be willing and able to comply with an early second-look URS [102] and stringent surveillance; complete tumour resection or destruction is necessary [102]. Nevertheless, there is still a risk of disease progression after endoscopic management owing to the suboptimal performance of imaging and biopsy for risk stratification and tumour biology [103]. A systematic review revealed comparable sur-

vival outcomes for endoscopic treatment to RNU at the cost of higher local recurrence rates and repeated interventions, but with some uncertainties regarding long-term renal preservation after endoscopic treatment [104].

Tumour ablation of UTUC during URS is typically performed using holmium and/or thulium lasers, which allow tumour resection while minimising damage. The procedure involves direct visual identification of the tumour before laser vaporisation or excision, which is often followed by meticulous irrigation to ensure that no residual tumour fragments remain.

Second-look URS after initial endoscopic treatment is recommended in the conservative management of UTUC to ensure complete tumour resection and evaluate residual disease, and should be performed within 8 wk after initial endoscopic treatment to assess for residual tumours or recurrence [102]. Other studies revealed that up to nearly 50% of patients had residual or recurrent disease on second-look URS, which emphasises the value of early follow-up [105]. Therefore, early second-look URS plays a crucial role in optimising the outcomes of conservative treatment for UTUC by ensuring thorough tumour control.

3.5.1.3. Percutaneous management. Percutaneous management can be considered for low-risk UTUC in the renal pelvis [99,106]. This option may also be offered for low-risk tumours in the lower caliceal system that are inaccessible or difficult to manage via flexible URS.

3.5.1.4. Ureteral resection. Segmental or distal ureterectomy and ureteral resection with adequate margins, ideally supported by frozen section analysis, provides sufficient pathological specimens for staging and grading while preserving the ipsilateral kidney. Direct anastomoses using either an end-to-end technique or ureteroneocystostomy are usually performed, but ileal-ureteral substitution or renal autotransplantation is also technically feasible, depending on the length of ureter removed [107,108]. Segmental resection of the proximal two-thirds of the ureter is associated with higher failure rates than for the distal ureter [109]. The cumulative incidence of ipsilateral upper tract recurrence is lower after distal ureterectomy with ureteroneocystostomy for tumours in the distal ureter (0–18%) [110,111] than after endourological kidney-sparing surgery (25–85%) [104].

3.5.1.5. Adjuvant instillations.

3.5.1.5.1. Upper urinary tract. Antegrade instillation of BCG or mitomycin C in the upper urinary tract via percutaneous nephrostomy after complete tumour eradication has been investigated for kidney-sparing management of CIS [112,113]. Retrograde instillation through a single-J open-ended ureteric stent is also used. A nephroureterogram is needed before both the antegrade and retrograde approaches to rule out ureteric obstruction or leakage, to confirm that there is no infection, and to ensure a low-pressure system to avoid pyelovenous influx during instillation and perfusion. The reflux obtained from a double-J stent has been used, but this approach is suboptimal because the drug often does not reach the renal pelvis [114–117]. The oncological benefit is unproven. Further evidence suggests that an early single adjuvant intracavitary instillation of mitomycin C in the upper tract for patients with low-grade UTUC might reduce the risk of local recurrence [118].

3.5.1.5.2. Bladder. There are currently no data to support the use of bladder instillation of chemotherapy after kidney-sparing surgery, as the randomised controlled trials (RCTs) available included only patients who underwent RNU.

3.5.2. Localised high-risk disease

3.5.2.1. Radical nephroureterectomy.

3.5.2.1.1. Surgical approach. Although the open approach for RNU has long been standard [7], laparoscopic and robot-assisted RNU can both be used to treat high-risk UTUC and provide perioperative benefits such as a lower risk of complications and shorter hospital stays [119–122]. In addition, equivalent oncological outcomes for all three procedures have been reported [119–121,123–127], except for a higher risk of intravesical recurrence after robotic RNU [128]. It is noteworthy that although laparoscopic RNU was historically purported to provide inferior oncological outcomes in locally advanced UTUC [129], with a higher risk of retroperitoneal dissemination or trocar metastases [130,131], this was not confirmed for robotic RNU [128].

Regardless of the approach, RNU must be performed according to oncological principles to prevent tumour seeding:

1. Perform en bloc removal of the kidney, ureter, and bladder cuff.
2. Avoid entry into the urinary tract, except when performing bladder cuff excision and only after prior clipping of the ureter and complete drainage of the bladder.

3.5.2.1.2. Bladder cuff management. Resection of the distal ureter and its orifice is performed because there is a considerable risk of tumour recurrence in this area and in the bladder [15,132–135]. Several techniques to simplify distal ureter resection have been considered, including the pluck technique, stripping, transurethral resection of the intramural ureter, and intussusception. There is no convincing evidence that any of these techniques is equal to complete bladder-cuff excision [16,133].

3.5.2.2. Lymph node dissection. There is no high-level evidence to support the use of LN dissection (LND) for upper tract tumours. However, template-based LND and the completeness of the dissection may improve CSS and reduce the risk of local recurrence [136]. Given that the risk of LN metastasis decreases with lower tumour stage [137], LND is probably unnecessary in patients with Ta/T1 UTUC [138,139]. However, preoperative clinical tumour staging is inaccurate; therefore, a template-based LND should be offered to all patients with high-risk disease who are scheduled for RNU, especially given the low risk of major postoperative complications [140]. The templates for LND vary according to primary tumour location [136,141,142] and their use is likely to have a greater impact on survival than the number of LNs removed [143].

3.5.2.3. Kidney-sparing surgery.

3.5.2.3.1. Elective indications. Distal ureterectomy: Distal ureterectomy, especially with adequate surgical margins according to frozen section analysis, followed by ureteroneocystostomy for high-risk UTUC located in the distal ureter only may be associated with similar oncological outcomes to those after RNU [97,98,144,145]. This procedure can be performed with concomitant LND. However, given the low level of evidence, this approach should only be used in highly selected cases for which the benefits may be greater than the potential risks.

Ureterorenoscopy or segmental ureterectomy: For patients with high-risk UTUC but harbouring low-grade disease without any infiltrative features at imaging, tumour size, multifocality, or hydronephrosis cannot be systematically considered as an indication for RNU [146,147]. Alternatively, ureterorenoscopy with laser ablation or segmental ureterectomy can be proposed on a case-by-case basis if feasible.

3.5.2.3.2. Imperative indications. Ureterorenoscopy with laser ablation or segmental ureterectomy can be considered on a case-by-case basis for patients with high-risk UTUC and imperative kidney-sparing indications. However, there is a greater risk of progression after kidney-sparing surgery for high- versus low-risk UTUC, with a direct impact on survival [97].

3.5.2.4. Perioperative chemotherapy.

3.5.2.4.1. Neoadjuvant treatments. Chemotherapy: The primary advantage of neoadjuvant chemotherapy (NAC) is the ability to give cisplatin-based regimens when patients still have maximal renal function. No RCTs have been published to date, but prospective data from phase 2 trials showed that NAC based on cisplatin combination therapy was associated with a pathological complete response rate of 14–19% in high-grade and/or cT2–T4 N0 M0 UTUC [148,149]. In addition, final pathological stage was <ypT1 in more than 60% of the patients included, with an acceptable toxicity profile. In a systematic review and meta-analysis involving more than 800 patients, NAC led to a pathological partial response rate of 43% and downstaging in 33% of patients, resulting in OS and CSS benefits in comparison to RNU alone [150]. Nevertheless, the review recommended adjuvant rather than neoadjuvant treatment.

Table 6 – Definitions of platinum eligibility for systemic treatment of urothelial carcinoma [2]

Platinum-eligible		Platinum-ineligible
Cisplatin-eligible	Carboplatin-eligible [a]	
ECOG PS 0-1 **and**GFR > 50–60 ml/min **and**Audiometric hearing loss grade <2 **and**Grade <2 peripheral neuropathy **and**NYHA class <III cardiac insufficiency	ECOG PS 2 **or**GFR 30–60 ml/min **or**Not fulfilling other cisplatin-eligibility criteria	Any of the following: • GFR <30 ml/min • ECOG PS >2 • ECOG PS 2 **and** GFR <60ml/min • Grade >2 comorbidities

ECOG PS = Eastern Cooperative Oncology Group performance status; GFR = glomerular filtration rate; NYHA = New York Heart Association.
[a] Carboplatin is not indicated for neoadjuvant treatment.

Immunotherapy: Only a small phase 2 study involving ten patients with high-risk UTUC has evaluated the efficacy of pembrolizumab in the neoadjuvant setting [151]. However, no pathological response was observed and one treatment-related death was reported. Thus, there is currently no evidence to support the use of neoadjuvant immunotherapy for high-risk UTUC.

3.5.2.4.2. Adjuvant treatments. Bladder instillations: The rate of bladder recurrence after RNU for UTUC is 22–47% [133,152]. Two prospective randomised trials [153,154] and two meta-analyses [155,156] have demonstrated that a single postoperative dose of intravesical chemotherapy (mitomycin C or pirarubicin) 2–10 d after surgery reduces the risk of bladder tumour recurrence within the first years after RNU for patients without a history of BC. Before instillation, a cystogram can be considered if there is concern about drug extravasation. On the basis of current evidence, it is unlikely that additional instillations beyond one perioperative instillation of chemotherapy further substantially reduce the risk of intravesical recurrence [157]. There are currently no data to support the use of bladder instillation of chemotherapy after kidney-sparing surgery, as the RCTs available included only patients who underwent RNU.

Systemic chemotherapy: The multicentre prospective phase 3 POUT RCT (n = 261) evaluated the benefit of four cycles of adjuvant chemotherapy with gemcitabine + platinum initiated within 90 d after RNU versus surveillance. The results revealed a significant improvement in DFS for patients with pT2–pT4 N_{any} or pT_{any} N1–3 M0 UTUC. Updated analysis showed 5-yr DFS rates of 62% versus 45% (hazard ratio [HR] 0.55, 95% CI 0.38–0.80; p = 0.001),

Table 7 – Recommendations for the management of high-risk nonmetastatic UTUC

Recommendation	Strengthrating
Discuss all cases with a suspicion of UTUC on imaging in a multidisciplinary team meeting.	Strong
Perform RNU in patients with high-risk nonmetastatic UTUC.	Strong
Use an open, laparoscopic, or robotic approach to perform RNU in patients with high-risk nonmetastatic UTUC.	Weak
Perform template-based lymphadenectomy in patients with high-risk nonmetastatic UTUC.	Weak
Offer platinum-based aCTx after RNU to eligible patients with pT2–T4 and/or pN+ disease.	Strong
Deliver a postoperative bladder instillation of chemotherapy to reduce the intravesical recurrence rate in patients without a history of bladder cancer.	Strong
Discuss adjuvant nivolumab with PD-L1-positive patients unfit for, or who decline, platinum-based aCTx for ≥pT3 and/or pN+ disease after RNU alone, or ≥ypT2 and/or ypN+ disease after NAC and RNU.	Weak
Discuss adjuvant pembrolizumab with patients unfit for, or who declined, platinum-based aCTx for ≥ pT3 and/or pN+ and/or positive-margin disease after RNU alone, or ≥ypT2 and/or ypN+ and/or positive-margin disease after previous NAC and RNU.	Weak
Offer distal ureterectomy to selected patients with high-risk tumours limited to the distal ureter.	Weak
Discuss kidney-sparing management for high-risk cases with an imperative indication on a case- by-case basis in a shared-decision making process with the patient despite the higher risk of disease progression.	Strong

aCTx = adjuvant chemotherapy; NAC = neoadjuvant chemotherapy; RNU = radical nephroureterectomy; UTUC = upper tract urothelial carcinoma.

and the mean restricted survival time was 18 mo longer in the chemotherapy arm. The 5-yr OS rates were 66% versus 57%, with a univariate HR of 0.68 (95% CI 0.46–1.00; p = 0.49). The treatment effect was consistent across chemotherapy regimens (carboplatin or cisplatin) and disease stage [158]. With a split dose and hydration, cisplatin may be considered in patients with a glomerular filtration rate as low as 45 ml/min. Table 6 outlines the eligibility criteria for platinum chemotherapy.

A retrospective study revealed different survival rates for histological UTUC subtypes, and adjuvant chemotherapy was only associated with an OS benefit for patients with pure UC [159]. Even though survival rates differed by histological UTUC subtype in retrospective studies, adjuvant chemotherapy should be considered whenever UC is the dominant histology (Table 7).

Systemic immunotherapy: In a multicentre, double-blind phase 3 RCT involving patients with high-risk muscle-invasive UC (pT3, pT4a, or pN+) who had undergone radical surgery, adjuvant nivolumab improved DFS in comparison to placebo in the intention-to-treat population (20.8 vs 10.8 mo) and in the subgroup with a PD-L1 expression level of ≥1% [160]. The patient population predominantly consisted of patients with BC who had undergone radical cystectomy, with an additional smaller cohort of patients with UTUC treated with RNU (approx. 25%). Subgroup analysis revealed that patients with UTUC included in this study did not seem to benefit from adjuvant nivolumab, which is a finding that requires further follow-up and analysis. Nonetheless, the European Medicines Agency approved nivolumab as monotherapy for adjuvant treatment of muscle-invasive UC in patients with tumour-cell PD-L1 expression >1% who are at high risk of recurrence after radical surgery and who decline or are unfit for adjuvant chemotherapy [161]. In a further study, 702 patients with UC treated with either radical cystectomy or RNU and with persistent high-risk features were randomised to receive either adjuvant pembrolizumab or observation [162]. DFS was significantly longer with pembrolizumab (29.6 vs 14.2 mo); however, the number of patients with UTUC (25% of the overall population) in the study was small, and subgroup analyses revealed that they did not seem to benefit from adjuvant pembrolizumab [162].

A network meta-analysis suggested that adjuvant platinum-based chemotherapy (PBC) yields a superior oncological benefit over immune checkpoint inhibitors in patients treated with radical surgery for UTUC [163].

Radiotherapy: It has been suggested that adjuvant radiotherapy controls locoregional disease after surgical removal of the tumour. The data remain controversial and insufficient for definitive conclusions [164–167]. Moreover, the value that radiotherapy adds to chemotherapy remains questionable [166].

3.5.3. Metastatic disease

3.5.3.1. Clinical locoregional LN metastases. Patients with resectable cN+ disease should be offered induction PBC (Table 8). RNU with template-based LND can be discussed in a multidisciplinary team and with patients who respond to initial systemic therapy. For patients whose cancer progresses, second-line treatment can be offered, similar to the approach for distant metastatic disease [168,169]. Patients with unresectable cN+ disease should be treated as for patients with distant metastatic UTUC [170].

Table 8 – Recommendations for the treatment of metastatic upper urinary tract urothelial carcinoma

Recommendation	Strength rating
Offer EV +P as first-line treatment to patients with advanced/metastatic disease.	Strong
First-line treatment for platinum-eligible patients unsuitable/ineligible for EV + P	
Offer platinum combination chemotherapy to platinum-eligible patients.	Strong
Offer cisplatin-based chemotherapy with gemcitabine-cisplatin + nivolumab to cisplatin-eligible patients	Weak
Offer cisplatin-based chemotherapy with gemcitabine/cisplatin or HD-MVAC to cisplatin-eligible patients.	Strong
Offer gemcitabine/carboplatin chemotherapy to cisplatin-ineligible patients.	Strong
Offer maintenance avelumab to patients who did not have disease progression after 4–6 cycles of platinum-based combination chemotherapy.	Strong
First-line treatment for patients ineligible for any combination therapy	
Offer pembrolizumab or atezolizumab to patients with PD-L1-positive tumours.	Weak
Later lines of treatment	
Offer platinum-based combination chemotherapy as a second-line treatment of choice if not received in the first-line setting.	Strong
Offer pembrolizumab to patients with disease progression during or after platinum-based combination chemotherapy for metastatic disease who did not receive maintenance avelumab.	Strong
Offer EV to patients previously treated with platinum-containing chemotherapy and who had disease progression during or after treatment with a PD-1 or PD-L1 inhibitor.	Strong
Offer erdafitinib as an alternative subsequent-line therapy to patients: • Previously treated with platinum-containing chemotherapy; • Who had disease progression during or after treatment with a PD-1 or PD-L1 inhibitor; • Who harbour *FGFR* DNA genomic alterations (*FGFR2/3* mutations or *FGFR3* fusions).	Strong
Only offer vinflunine as a second-line treatment to patients with metastatic disease if immunotherapy or combination chemotherapy is not feasible. Alternatively, offer vinflunine as a third- or subsequent-line treatment.	Strong
Offer nephroureterectomy as a palliative treatment to symptomatic patients with resectable locally advanced tumours.	Weak

EV + P = enfortumab vedotin combined with pembrolizumab; HD-MVAC = high-dose methotrexate, vinblastine, adriamycin, and cisplatin.

3.5.3.2. Distant metastases.

3.5.3.2.1. Systemic treatments in the first-line setting. Enfortumab vedotin + pembrolizumab combination therapy: For more than 23 yr, despite multiple attempts with new agents and/or treatment combinations, PBC remained standard of care for previously untreated advanced or metastatic UC. In October 2023, the landscape changed dramatically on publication of results from the multicentre phase 3 randomised EV302 study. The study compared the nectin 4–directed antibody-drug conjugate enfortumab vedotin combined with the checkpoint inhibitor pembrolizumab (EV + P) to platinum-based combination chemotherapy

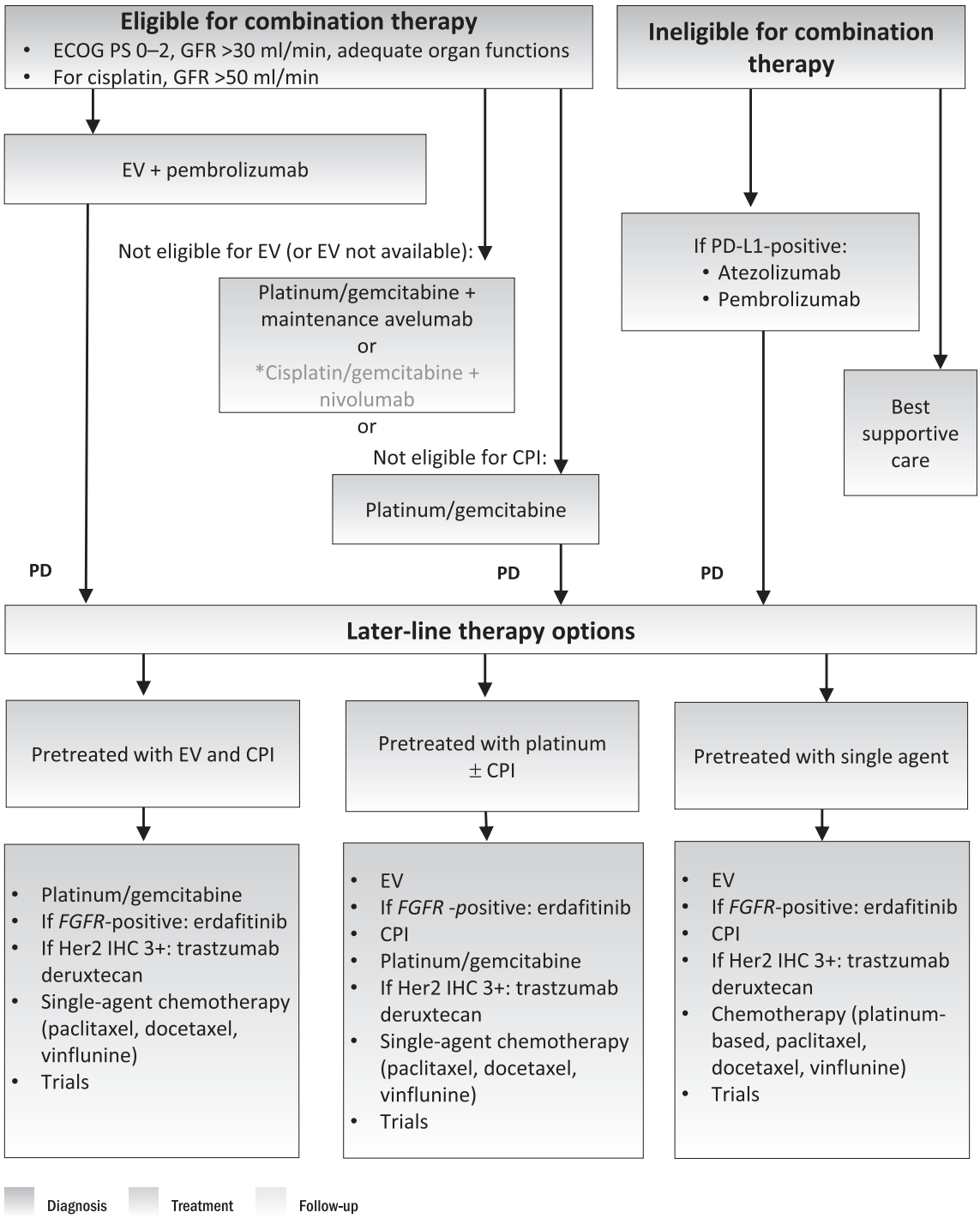

Fig. 5 – Flowchart for the management of metastatic upper urinary tract urothelial carcinoma. CPI = checkpoint inhibitor; ECOG PS = Eastern Cooperative Oncology Group performance status; EV = enfortumab vedotin; GFR = glomerular filtration rate; PD = progressive disease.

(gemcitabine-cisplatin or gemcitabine-carboplatin; Table 6 lists the cisplatin eligibility criteria).

This study showed significant improvements in both progression-free survival (PFS; HR 0.45, 95% CI 0.38–0.54) and OS (HR 0.47, 95% CI 0.38–0.58), with a response rate of 68% for EV + P (vs 44% for chemotherapy) and a complete response rate of 29%. An OS benefit was seen across subgroups regardless of cisplatin eligibility. The most common grade ≥3 treatment-related adverse events of special interest included skin reactions (15.5%), peripheral neuropathy (6.8%), and hyperglycaemia (6.1%). The proportion of UTUC patients in this study was 25% and preplanned subgroup analysis showed a benefit irrespective of tumour location [171].

Sequencing of treatment after EV + P is currently unclear, and later-line treatments will depend on what agents the patient has previously received (Fig. 5).

Patients ineligible for EV + P and fit for cisplatin-based combination chemotherapy: UTUC and bladder UC both respond to systemic PBC. Eligibility to PBC in the metastatic setting is based on the same criteria as outlined in Table 6. A retrospective analysis of three RCTs showed that primary tumour location in the lower or upper urinary tract had no impact on PFS or OS in patients with locally advanced or metastatic UC treated with platinum-based combination chemotherapy [172]. Therefore, cisplatin-containing combination chemotherapy is the standard treatment for advanced or metastatic UTUC ineligible for EV + P [2].

A phase 3 RCT in advanced/metastatic UC has now revealed an overall benefit from addition of nivolumab to chemotherapy (gemcitabine-cisplatin), with improvements in median OS (21.7 vs 18.9 mo; HR 0.78, 95% CI 0.63–0.96) and median PFS (7.9 vs 7.6 mo; HR 0.72, 95% CI 0.59–0.88). The objective response rate was 57.6% versus 43.1% for chemotherapy alone [173]. Although there was no subgroup analysis by tumour location in the study, 12.6% of patients had UTUC.

Patients ineligible for EV + P and unfit for cisplatin-based combination chemotherapy: Carboplatin-based chemotherapy is recommended for patients who are unfit for cisplatin [2]. Carboplatin with gemcitabine is the preferred regimen [174], irrespective of PD-L1 status.

Maintenance therapy after first-line PBC: Maintenance avelumab is recommended for patients with a complete/-partial response or stable disease after 4–6 cycles of PBC given in the first-line setting. Data from a phase 3 RCT showed that avelumab maintenance therapy after 4–6 cycles of gemcitabine plus cisplatin or carboplatin (started within 10 wk of completion of first-line PBC) significantly prolonged OS in comparison to best supportive care alone for patients with advanced or metastatic UC who did not experience disease progression during, or responded to, first-line chemotherapy (HR 0.69, 95% CI 0.56–0.86) [175,176].

Patients unfit for any combination therapy: Pembrolizumab or atezolizumab are alternative choices for patients who are PD-L1-positive and not eligible or fit for PBC. In a single-arm phase 2 trial involving 370 cisplatin-ineligible patients with UC, pembrolizumab monotherapy was associated with an objective response rate of 26% in the cohort of 69 patients with metastatic UTUC [177]. In a single-arm phase 2 trial involving 119 cisplatin-ineligible patients with UC, atezolizumab monotherapy was associated with an objective response rate of 39% in the cohort of 33 patients (28%) with metastatic UTUC [178].

3.5.3.2.2. Systemic treatments in later lines. Subsequent treatments depend on the type of treatment given in the first-line setting.

Platinum based chemotherapy: Platinum-based chemotherapy should be the second-line treatment of choice if not received in the first-line setting.

Immunotherapy: A phase 3 RCT involving 542 patients who had received first-line PBC for advanced UC showed that pembrolizumab decreased the risk of death in comparison to second-line chemotherapy (investigator's choice of paclitaxel, docetaxel, or vinflunine); median OS was 10.3 mo with pembrolizumab and 7.4 mo with chemotherapy (HR 0.73, 95% CI 0.59–0.91) [179]. Responses were more frequent and durable for pembrolizumab versus chemotherapy (21% vs 11%). The OS benefit was greater (50%) in the UTUC subgroup (n = 75, 13.8%).

FGFR inhibitors: Erdafitinib is a pan-FGFR tyrosine kinase inhibitor of FGFR1–4. The phase 3 Thor trial randomised 266 patients with advanced UC and a genomic *FGFR* alteration (FGFR2/3 mutations or FGFR3 fusions) who had experienced disease progression after one or two previous treatment lines to treatment with either erdafitinib or investigator's choice of chemotherapy (vinflunine or docetaxel). Significant improvements in median OS (4.3 mo; HR 0.64, 95% CI 0.47–0.88) and median PFS (2.9 mo; HR 0.58, 95% CI 0.44–0.78) and a 36% reduction in the risk of death were observed. Some 33.5% of patients in this study had UTUC [180]. As the rate of activating *FGFR3* alterations is higher in UTUC than in BC [181], a potentially greater impact of FGR3-targeted agents is anticipated. Patients with UTUC should be tested for *FGFR* alterations before erdafitinib treatment. Early testing for *FGFR 2/3* mutations or deletions should be considered for patients presenting with advanced/metastatic UTUC (Table 3).

Antibody-drug conjugates: A phase 2 study enrolled 89 cisplatin-unfit patients (of whom 43% had UTUC) with metastatic UC who experienced disease progression after PD-1/PD-L1 inhibitor therapy. All patients received the antibody-drug conjugate EV. The objective radiological response rate (RECIST) was 52%, and 20% of patients achieved a complete response [182]. In a phase 3 trial of EV treatment for locally advanced or metastatic UC in patients who had previously received PBC and had disease progression during or after PD-1/PD-L1 inhibitor treatment, EV significantly prolonged OS in comparison to standard chemotherapy (median OS 12.88 vs 8.97 mo) [183].

Radical nephroureterectomy: Data regarding RNU in the metastatic setting are lacking, with mainly retrospective observational studies available [184–186]. Although the evidence is very limited, RNU may be associated with CSS [185,187,188] and OS benefits in selected patients, especially those fit enough to receive cisplatin-based chemotherapy [184,185]. It is noteworthy that these benefits may be limited to patients with only one metastatic site [185]. Given the high risk of bias in observational studies on RNU for metastatic UTUC, indications for RNU in this setting should mainly be reserved for palliative strategies to control symptomatic disease [11,189].

Metastasectomy: There is no UTUC-specific study supporting the role of metastasectomy in patients with advanced disease. Reports suggesting that resection of metastatic lesions could be safe and oncologically beneficial in selected patients should be interpreted with caution

Table 9 – Recommendations for follow-up of upper urinary tract urothelial carcinoma

Recommendation	Strength rating
After radical nephroureterectomy	
Low-risk tumours	
Perform CYS at 3 mo; if negative, perform CYS 9 mo later and then yearly for 5 yr.	Weak
High-risk tumours	
In patients with a history of NMIBC, perform CYS and VUC at 3 mo; if negative, repeat CYS and VUC every 3 mo up to 2 yr, every 6 mo up to 5 yr, and yearly thereafter.	Weak
In patients without a history of NMIBC, perform CYS and VUC at 3 mo; if negative, repeat CYS and VUC every 6 mo up to 2 yr, and then every year up to 5 yr.	Weak
Perform CT urography and chest CT every 6 mo for 2 yr, and then yearly.	Weak
After kidney-sparing management	
Low-risk tumours	
For bladder follow-up, perform CYS at 3 and 6 mo, and then yearly for 5 yr.	Weak
For upper tract follow-up, after negative second-look URS, perform CSIU at 3 and 6 mo, and then yearly for 5 yr, with or without URS [a].	Weak
High-risk tumours	
In patients without a history of NMIBC, follow-up is the same as for high-risk tumours after RNU.	Weak
For upper tract follow-up, after negative second-look URS, perform CSIU and URS at 3 and 6 mo, then CSIU every 6 mo for 2 yr, and then every year for 5 yr, with or without URS [a].	Weak

CSIU = cross-sectional imaging urography; CT = computed tomography; CYS = cystoscopy; NMIBC = non–muscle-invasive bladder cancer; URS = ureteroscopy; VUC = voided urine cytology.

[a] The role of URS of the ipsilateral upper urinary tract versus CT urography and VUC during follow-up after endourological kidney-sparing treatment is unknown.

[190–192]. In the absence of RCT data, patients should be evaluated on an individual basis and surgical metastasectomy should only be chosen following a shared decision-making process with the patient.

3.5.4. Follow-up

The aims for follow-up after treatment for UTUC are to meet patient rehabilitation needs and to detect recurrent or new primary tumours within the urothelium, and regional and/or distant metastases. Bladder recurrence is not considered distant recurrence. Unfortunately, the heterogeneity of studies on disease recurrence in UTUC is significant, and the evidence for recommendations for follow-up is of a low level at best.

Surveillance regimens are based on CT urography, cystoscopy, and urinary cytology [193,194]. However, there are several unanswered questions related to optimal follow-up for patients treated for low-risk or high-risk UTUC, including:

- The added value of new urinary markers in comparison to cytology for voided urine samples in patients with high-risk UTUC [195];
- The effect of the Paris system on the sensitivity and specificity of voided and selective urine cytology during UTUC follow-up for high-risk tumours [196];
- Whether less intensive follow-up is suitable after administration of upper tract instillations following endourological kidney-sparing management; and
- The role of URS of the ipsilateral upper urinary tract versus CT urography and voided urinary cytology during follow-up after endourological kidney-sparing treatment.

In addition, it is not known how patients with Lynch syndrome, without or with UTUC, should be screened or followed in the long term given the inadequacy of surveillance based on urinalysis for nonvisible haematuria [197] and urine cytology [198], particularly for individuals with *MSH2* mutations [27] and those who already have UTUC. Table 9 presents the recommendations for follow-up of UTUC.

3.5.5. Quality indicators for UTUC management

Evidence-based quality indicators (QIs) and quality performance indicators have been designed as surrogates of good practice and consequently, outcomes. These metrics narrow the gap between efficacy and effectiveness: research evidence and guideline recommendations are brought into real-world practice by improving QI compliance [199]. They also allow objective monitoring of the quality of care and thus facilitate quality control and service improvements.

No QIs have been proposed for the overall management of UTUC. QIs remain to be defined for UTUC diagnosis, treatment of low-risk or metastatic disease, and further follow-up. However, several QIs have been proposed for perioperative management of high-risk cases treated with RNU, including complete bladder cuff removal, concomitant tailored LND, early postoperative single bladder instillation of chemotherapy, and risk-adapted delivery of neoadjuvant or adjuvant systemic treatments [200].

In addition, it has been shown that achievement of an RNU-specific pentafecta of negative surgical margins, complete bladder cuff removal, and the absence of haematological or major complications and postoperative recurrence at 12 mo is associated with higher 5-yr OS and CSS rates [201]. Similar results have been observed for achievement of an RNU-specific tetrafecta comprising negative surgical margins, complete bladder cuff removal, guideline-based LND, and the absence of postoperative recurrence at 12 mo [202]. Finally, an annual hospital volume of more than six RNU procedures was associated with better short-term outcomes (30-d and 90-d mortality) and long-term OS in a population-based study [203].

Author contributions: Alexandra Masson-Lecomte had full access to all the data in the study and takes responsibility for the integrity of the data and the accuracy of the data analysis.

Study concept and design: Masson-Lecomte, Birtle, Pradere, Capoun, Compérat, Dominguez-Escrig, Liedberg, Makaroff, Mariappan, Moschini, Rai, van Rhijn, Shariat, Teoh, Soukup, Wood, Xylinas, Soria, Seisen, Gontero.
Acquisition of data: Masson-Lecomte, Birtle, Pradere, Capoun, Compérat, Dominguez-Escrig, Liedberg, Makaroff, Mariappan, Moschini, Rai, van Rhijn, Shariat, Teoh, Soukup, Wood, Xylinas, Soria, Seisen, Gontero.
Analysis and interpretation of data: Masson-Lecomte, Birtle, Pradere, Capoun, Compérat, Dominguez-Escrig, Liedberg, Makaroff, Mariappan, Moschini, Rai, van Rhijn, Shariat, Teoh, Soukup, Wood, Xylinas, Soria, Seisen, Gontero.

Drafting of the manuscript: Masson-Lecomte.
Critical revision of the manuscript for important intellectual content: Masson-Lecomte, Birtle, Pradere, Capoun, Compérat, Dominguez-Escrig, Liedberg, Makaroff, Mariappan, Moschini, Rai, van Rhijn, Shariat, Teoh, Soukup, Wood, Xylinas, Soria, Seisen, Gontero.
Statistical analysis: None.
Obtaining funding: None.
Administrative, technical, or material support: Smith.
Supervision: Masson-Lecomte.
Other: None.

Financial disclosures: Alexandra Masson-Lecomte certifies that all conflicts of interest, including specific financial interests and relationships and affiliations relevant to the subject matter or materials discussed in the manuscript (eg, employment/affiliation, grants or funding, consultancies, honoraria, stock ownership or options, expert testimony, royalties, or patents filed, received, or pending), are the following: Alexandra Masson-Lecomte is a consultant for Ferring, Pfizer, Lilly, AstraZeneca, Astellas, Photocure, and Janssen (Johnson & Johnson); receives speaker honoraria from Merck, Janssen, Ipsen, Medac, and BMS; participates in trials run by MSD and Janssen; and has received research and/or educational funding from Janssen and Ipsen. Paolo Gontero is a consultant for Ferring, Nucleix, MSD, Pfizer, AstraZeneca, Medac, and Photocure; receives speaker honoraria from Merck, Janssen, Ipsen, Medac, and Ferring; participates in trials run by Ferring, Janssen, and Catalym; and has received research and/or educational funding from Ab Medica, Astellas, Ferring, and Ipsen. Bas W.G. van Rhijn has attended advisory board meetings for QED Therapeutics and Incyte International Biosciences. Evanguelos N. Xylinas is a speaker for Ipsen Pharma, Janssen-Oncology, Ferring, BMS, MSD, and Merck; an advisory board member for Ipsen Pharma, Janssen, Ferring, Astellas, MSD, BMS, and Merck; and an investigator and steering committee member for AstraZeneca, Bayer, Ferring, Ipsen, Janssen-Oncology, MSD, Pfizer, and QED. Thomas Seisen has received honoraria from Janssen, Astellas, BMS, Ipsen, Bayer, Pfizer, ADACAP, MSD, and VitaDX; and participates in trials run by Roche and Janssen. José L. Domínguez-Escrig is a proctor for Presurgy and Angiodynamics; receives speaker honoraria from Presurgy and Angiodynamics; and participates in trials run by Janssen, Arquer, Physion, Combat BRS, Ipsen, Storz, Uromonitor, Fidia Farmaceutici, and Angiodynamics. Alison Birtle has acted as a consultant for Bayer, Merck, and Janssen; has received honoraria and/or educational support from Astellas, Bayer, Janssen, Novartis, Accelerated Applications, Ipsen, Roche, MSD, Merck, and Accord; and is an advisory board member or speaker for Merck, MSD, Astellas, Johnson & Johnson, Bayer, Macrogenics, Pfizer, and AstraZeneca. Francesco Soria participates in advisory boards for Johnson & Johnson and Photocure; and is a consult and speaker for Medac. Jeremy Y.-C. Teoh is a consultant for J&J Innovative Medicine, Ferring, Phase Scientific, CMR Robotics, and Procept BioRobotics; receives speaker honoraria from Ferring, MSD, Baxter, and Olympus; participates in trials run by Astellas, BMS, J&J Innovative Medicine, and MSD, and has received research funding from Baxter, Ferring, and Olympus. Marco Moschini is an advisory board member for Medac, Photocure, and Pfizer. The remaining authors have nothing to disclose. Bhavan P. Rai received honoraria for speaker fees and/or educational support from Bayer Plc, Ipsen Developments Ltd, Janssen-Cilag Ltd.

***Funding/Support and role of the sponsor*:** This work was supported by the European Association of Urology. The sponsor played a role in collection and management of the data, and preparation and review of the manuscript.

References

[1] Gontero P, Compérat E, Dominguez-Escrig JL, et al. EAU guidelines on non-muscle-invasive bladder cancer (T1, T1 and CIS). Arnhem, The Netherlands: European Association of Urology; 2025.
[2] van der Heijden AG, Compérat E, Cowan N, et al. EAU guidelines on muscle-invasive and metastatic bladder cancer. Arnhem, The Netherlands: European Association of Urology; 2025.
[3] Neuzillet Y, Witjes JA, Compérat E, et al. EAU guidelines on primary urethral carcinoma. Arnhem, The Netherlands: European Association of Urology; 2025.
[4] Guyatt GH, Oxman AD, Kunz R, et al. Going from evidence to recommendations. BMJ 2008;336:1049–51.
[5] Siegel RL, Miller KD, Wagle NS, Jemal A. Cancer statistics, 2023. CA Cancer J Clin 2023;73:17–48.
[6] Shariat SF, Favaretto RL, Gupta A, et al. Gender differences in radical nephroureterectomy for upper tract urothelial carcinoma. World J Urol 2011;29:481–6.
[7] Margulis V, Shariat SF, Matin SF, et al. Outcomes of radical nephroureterectomy: a series from the Upper Tract Urothelial Carcinoma Collaboration. Cancer 2009;115:1224–11223.
[8] Browne BM, Stensland KD, Moynihan MJ, Canes D. An analysis of staging and treatment trends for upper tract urothelial carcinoma in the National Cancer Database. Clin Genitourin Cancer 2018;16, e743–50.
[9] Cosentino M, Palou J, Gaya JM, Breda A, Rodriguez-Faba O, Villavicencio-Mavrich H. Upper urinary tract urothelial cell carcinoma: location as a predictive factor for concomitant bladder carcinoma. World J Urol 2013;31:141–5.
[10] Singla N, Fang D, Su X, et al. A multi-institutional comparison of clinicopathological characteristics and oncologic outcomes of upper tract urothelial carcinoma in China and the United States. J Urol 2017;197:1208–13.
[11] Herr HW. Extravesical tumor relapse in patients with superficial bladder tumors. J Clin Oncol 1998;16:1099–102.
[12] Miller EB, Eure GR, Schellhammer PF. Upper tract transitional cell carcinoma following treatment of superficial bladder cancer with BCG. Urology 1993;42:26–30.
[13] Nishiyama N, Hotta H, Takahashi A, et al. Upper tract urothelial carcinoma following intravesical bacillus Calmette-Guerin therapy for nonmuscle-invasive bladder cancer: results from a multi-institutional retrospective study. Urol Oncol 2018;36, 306.e9–15.
[14] Sanderson KM, Roupret M. Upper urinary tract tumour after radical cystectomy for transitional cell carcinoma of the bladder: an update on the risk factors, surveillance regimens and treatments. BJU Int 2007;100:11–6.
[15] Seisen T, Granger B, Colin P, et al. A systematic review and meta-analysis of clinicopathologic factors linked to intravesical recurrence after radical nephroureterectomy to treat upper tract urothelial carcinoma. Eur Urol 2015;67:1122–33.
[16] Li WM, Shen JT, Li CC, et al. Oncologic outcomes following three different approaches to the distal ureter and bladder cuff in nephroureterectomy for primary upper urinary tract urothelial carcinoma. Eur Urol 2010;57:963–9.
[17] Green DA, Rink M, Xylinas E, et al. Urothelial carcinoma of the bladder and the upper tract: disparate twins. J Urol 2013;189:1214–21.
[18] Colin P, Koenig P, Ouzzane A, et al. Environmental factors involved in carcinogenesis of urothelial cell carcinomas of the upper urinary tract. BJU Int 2009;104:1436–40.
[19] Dickman KG, Fritsche HM, Grollman AP, Thalmann GN, Catto J. Epidemiology and risk factors for upper urinary urothelial cancers. In: Shariat SF, Xylinas E, editors. Upper tract urothelial carcinoma. New York, NY: Springer; 2015.
[20] McLaughlin JK, Silverman DT, Hsing AW, et al. Cigarette smoking and cancers of the renal pelvis and ureter. Cancer Res 1992;52:254–7.
[21] Crivelli JJ, Xylinas E, Kluth LA, Rieken M, Rink M, Shariat SF. Effect of smoking on outcomes of urothelial carcinoma: a systematic review of the literature. Eur Urol 2014;65:742–54.
[22] Grollman AP. Aristolochic acid nephropathy: harbinger of a global iatrogenic disease. Environ Mol Mutagen 2013;54:1–7.
[23] National Toxicology Program. Aristolochic acids. Rep Carcinog 2011;12:45–9.

[24] Cosyns JP. Aristolochic acid and 'Chinese herbs nephropathy': a review of the evidence to date. Drug Saf 2003;26:33–48.
[25] Koornstra JJ, Mourits MJ, Sijmons RH, Leliveld AM, Hollema H, Kleibeuker JH. Management of extracolonic tumours in patients with Lynch syndrome. Lancet Oncol 2009;10:400–8.
[26] Ju JY, Mills AM, Mahadevan MS, et al. Universal Lynch syndrome screening should be performed in all upper tract urothelial carcinomas. Am J Surg Pathol 2018;42:1549–55.
[27] Therkildsen C, Eriksson P, Hoglund M, et al. Molecular subtype classification of urothelial carcinoma in Lynch syndrome. Mol Oncol 2018;12:1286–95.
[28] Vasen HF, Watson P, Mecklin JP, Lynch HT. New clinical criteria for hereditary nonpolyposis colorectal cancer (HNPCC, Lynch syndrome) proposed by the International Collaborative group on HNPCC. Gastroenterology 1999;116:1453–6.
[29] Roupret M, Catto J, Coulet F, et al. Microsatellite instability as indicator of MSH2 gene mutation in patients with upper urinary tract transitional cell carcinoma. J Med Genet 2004;41:e91.
[30] Audenet F, Colin P, Yates DR, et al. A proportion of hereditary upper urinary tract urothelial carcinomas are misclassified as sporadic according to a multi-institutional database analysis: proposal of patient-specific risk identification tool. BJU Int 2012;110, E583–9.
[31] Roupret M, Yates DR, Comperat E, Cussenot O. Upper urinary tract urothelial cell carcinomas and other urological malignancies involved in the hereditary nonpolyposis colorectal cancer (Lynch syndrome) tumor spectrum. Eur Urol 2008;54:1226–36.
[32] Acher P, Kiela G, Thomas K, O'Brien T. Towards a rational strategy for the surveillance of patients with Lynch syndrome (hereditary non-polyposis colon cancer) for upper tract transitional cell carcinoma. BJU Int 2010;106:300–2.
[33] Gabriel PE, Cancel-Tassin G, Audenet F, et al. A collaborative review of the microsatellite instability/deficient mismatch repair phenotype in patients with upper tract urothelial carcinoma. BJU Int 2024;134:723–35.
[34] Gayhart MG, Johnson N, Paul A, et al. Universal mismatch repair protein screening in upper tract urothelial carcinoma. Am J Clin Pathol 2020;154:792–801.
[35] Schneider B, Glass A, Jagdmann S, et al. Loss of mismatch-repair protein expression and microsatellite instability in upper tract urothelial carcinoma and clinicopathologic implications. Clin Genitourin Cancer 2020;18, e563–72.
[36] Ito T, Kono K, Eguchi H, et al. Prevalence of Lynch syndrome among patients with upper urinary tract carcinoma in a Japanese hospital-based population. Jpn J Clin Oncol 2020;50:80–8.
[37] Rasmussen M, Madsen MG, Therkildsen C. Immunohistochemical screening of upper tract urothelial carcinomas for Lynch syndrome diagnostics: a systematic review. Urology 2022;165:44–53.
[38] Sakano S, Matsuyama H, Kamiryo Y, et al. Impact of variant histology on disease aggressiveness and outcome after nephroureterectomy in Japanese patients with upper tract urothelial carcinoma. Int J Clin Oncol 2015;20:362–8.
[39] Ouzzane A, Ghoneim TP, Udo K, et al. Small cell carcinoma of the upper urinary tract (UUT-SCC): report of a rare entity and systematic review of the literature. Cancer Treat Rev 2011;37:366–72.
[40] Rink M, Robinson BD, Green DA, et al. Impact of histological variants on clinical outcomes of patients with upper urinary tract urothelial carcinoma. J Urol 2012;188:398–404.
[41] Mori K, Janisch F, Parizi MK, et al. Prognostic value of variant histology in upper tract urothelial carcinoma treated with nephroureterectomy: a systematic review and meta-analysis. J Urol 2020;203:1075–84.
[42] Zamboni S, Foerster B, Abufaraj M, et al. Incidence and survival outcomes in patients with upper urinary tract urothelial carcinoma diagnosed with variant histology and treated with nephroureterectomy. BJU Int 2019;124:738–45.
[43] Kim JK, Moon KC, Jeong CW, Kwak C, Kim HH, Ku JH. Variant histology as a significant predictor of survival after radical nephroureterectomy in patients with upper urinary tract urothelial carcinoma. Urol Oncol 2017;35, 458.e9–15.
[44] Malouf GG, Comperat E, Yao H, et al. Unique transcriptomic profile of collecting duct carcinomas relative to upper tract urothelial carcinomas and other kidney carcinomas. Sci Rep. 2016;6:30988.
[45] Hassler MR, Bray F, Catto JWF, et al. Molecular characterization of upper tract urothelial carcinoma in the era of next-generation sequencing: a systematic review of the current literature. Eur Urol 2020;78:209–20.
[46] Soukup V, Capoun O, Cohen D, et al. Prognostic performance and reproducibility of the 1973 and 2004/2016 World Health Organization grading classification systems in non-muscle-invasive bladder cancer: a European Association of Urology Non-muscle Invasive Bladder Cancer Guidelines Panel systematic review. Eur Urol 2017;72:801–13.
[47] Subiela JD, Territo A, Mercade A, et al. Diagnostic accuracy of ureteroscopic biopsy in predicting stage and grade at final pathology in upper tract urothelial carcinoma: systematic review and meta-analysis. Eur J Surg Oncol 2020;46:1989–97.
[48] Brierley JD, Gospodarowicz MK, Wittekind C, editors. TNM classification of malignant tumours. Chichester, UK: Wiley; 2016.
[49] Sauter G. Tumours of the urinary system: non-invasive urothelial neoplasias. In: Sauter A, Amin M, editors. WHO classification of tumours of the urinary system and male genital organs. Lyon, France: IARC Press; 2004.
[50] Moch H, Humphrey PA, Ulbright TM, Reuter VE, editors. WHO classification of tumours of the urinary system and male genital organs. Lyon, France: IARC Press; 2016.
[51] WHO Classification of Tumours Editorial Board. WHO classification of tumours. Urinary and male genital tumours. 8th ed. Lyon, France: IARC; 2022.
[52] Baard J, Cormio L, Cavadas V, et al. Contemporary patterns of presentation, diagnostics and management of upper tract urothelial cancer in 101 centres: the Clinical Research Office of the Endourological Society Global upper tract urothelial carcinoma registry. Curr Opin Urol 2021;31:354–62.
[53] Raman JD, Shariat SF, Karakiewicz PI, et al. Does preoperative symptom classification impact prognosis in patients with clinically localized upper-tract urothelial carcinoma managed by radical nephroureterectomy? Urol Oncol 2011;29:716–23.
[54] Cowan NC, Turney BW, Taylor NJ, McCarthy CL, Crew JP. Multidetector computed tomography urography for diagnosing upper urinary tract urothelial tumour. BJU Int 2007;99:1363–70.
[55] Janisch F, Shariat SF, Baltzer P, et al. Diagnostic performance of multidetector computed tomographic (MDCTU) in upper tract urothelial carcinoma (UTUC): a systematic review and meta-analysis. World J Urol 2020;38:1165–75.
[56] Verhoest G, Shariat SF, Chromecki TF, et al. Predictive factors of recurrence and survival of upper tract urothelial carcinomas. World J Urol 2011;29:495–501.
[57] Pallauf M, D'Andrea D, Konig F, et al. Diagnostic accuracy of clinical lymph node staging for upper tract urothelial cancer patients: a multicenter, retrospective, observational study. J Urol 2023;209:515–24.
[58] Takahashi N, Glockner JF, Hartman RP, et al. Gadolinium enhanced magnetic resonance urography for upper urinary tract malignancy. J Urol 2010;183:1330–65.
[59] Voskuilen CS, Schweitzer D, Jensen JB, et al. Diagnostic value of ^{18}F-fluorodeoxyglucose positron emission tomography with computed tomography for lymph node staging in patients with upper tract urothelial carcinoma. Eur Urol Oncol 2020;3:73–9.
[60] Soria F, Shariat SF, Lerner SP, et al. Epidemiology, diagnosis, preoperative evaluation and prognostic assessment of upper-tract urothelial carcinoma (UTUC). World J Urol 2017;35: 379–87.
[61] Wojcik EM, Kurtycz DFI, Rosenthal DL, editors. The Paris system for reporting urinary cytology. Cham, Switzerland: Springer; 2022.
[62] Messer J, Shariat SF, Brien JC, et al. Urinary cytology has a poor performance for predicting invasive or high-grade upper-tract urothelial carcinoma. BJU Int 2011;108:701–5.
[63] Malm C, Grahn A, Jaremko G, Tribukait B, Brehmer M. Diagnostic accuracy of upper tract urothelial carcinoma: how samples are collected matters. Scand J Urol 2017;51:137–45.
[64] Bialek L, Bilski K, Dobruch J, et al. Non-invasive biomarkers in the diagnosis of upper urinary tract urothelial carcinoma—a systematic review. Cancers 2022;14:1520.
[65] Rojas CP, Castle SM, Llanos CA, et al. Low biopsy volume in ureteroscopy does not affect tumor biopsy grading in upper tract urothelial carcinoma. Urol Oncol 2013;31:1696–700.

[66] Mori K, Katayama S, Laukhtina E, et al. Discordance between clinical and pathological staging and grading in upper tract urothelial carcinoma. Clin Genitourin Cancer 2022;20, 95.e1–6.
[67] Smith AK, Stephenson AJ, Lane BR, et al. Inadequacy of biopsy for diagnosis of upper tract urothelial carcinoma: implications for conservative management. Urology 2011;78:82–6.
[68] Clements T, Messer JC, Terrell JD, et al. High-grade ureteroscopic biopsy is associated with advanced pathology of upper-tract urothelial carcinoma tumors at definitive surgical resection. J Endourol 2012;26:398–402.
[69] Brien JC, Shariat SF, Herman MP, et al. Preoperative hydronephrosis, ureteroscopic biopsy grade and urinary cytology can improve prediction of advanced upper tract urothelial carcinoma. J Urol 2010;184:69–73.
[70] Sharma V, Miest TS, Juvet TS, et al. The impact of upper tract urothelial carcinoma diagnostic modality on intravesical recurrence after radical nephroureterectomy: a single institution series and updated meta-analysis. J Urol 2021;206:558–67.
[71] Nowak L, Krajewski W, Chorbinska J, et al. The impact of diagnostic ureteroscopy prior to radical nephroureterectomy on oncological outcomes in patients with upper tract urothelial carcinoma: a comprehensive systematic review and meta-analysis. J Clin Med 2021;10:4197.
[72] Bus MT, de Bruin DM, Faber DJ, et al. Optical diagnostics for upper urinary tract urothelial cancer: technology, thresholds, and clinical applications. J Endourol 2015;29:113–23.
[73] Pouessel D, Neuzillet Y, Mertens LS, et al. Tumor heterogeneity of fibroblast growth factor receptor 3 (FGFR3) mutations in invasive bladder cancer: implications for perioperative anti-FGFR3 treatment. Ann Oncol 2016;27:1311–6.
[74] Loriot Y, Necchi A, Park SH, et al. Erdafitinib in locally advanced or metastatic urothelial carcinoma. N Engl J Med 2019;381:338–48.
[75] Colla Ruvolo C, Nocera L, Stolzenbach LF, et al. Incidence and survival rates of contemporary patients with invasive upper tract urothelial carcinoma. Eur Urol Oncol 2021;4:792–801.
[76] van Doeveren T, van der Mark M, van Leeuwen PJ, Boormans JL, Aben KKH. Rising incidence rates and unaltered survival rates for primary upper urinary tract urothelial carcinoma: a Dutch population-based study from 1993 to 2017. BJU Int 2021;128:343–51.
[77] Rosiello G, Palumbo C, Knipper S, et al. Contemporary conditional cancer-specific survival after radical nephroureterectomy in patients with nonmetastatic urothelial carcinoma of upper urinary tract. J Surg Oncol 2020;121:1154–61.
[78] Raman JD, Ng CK, Scherr DS, et al. Impact of tumor location on prognosis for patients with upper tract urothelial carcinoma managed by radical nephroureterectomy. Eur Urol 2010;57:1072–9.
[79] Yu J, Li G, Wang A, et al. Impact of squamous differentiation on intravesical recurrence and prognosis of patients with upper tract urothelial carcinoma. Ann Transl Med 2019;7:377.
[80] Perez-Montiel D, Wakely PE, Hes O, Michal M, Suster S. High-grade urothelial carcinoma of the renal pelvis: clinicopathologic study of 108 cases with emphasis on unusual morphologic variants. Mod Pathol 2006;19:494–503.
[81] McCoy JG, Honda H, Reznicek M, Williams RD. Computerized tomography for detection and staging of localized and pathologically defined upper tract urothelial tumors. J Urol 1991;146:1500–3.
[82] Almas B, Overby S, Halvorsen OJ, Reisaeter LAR, Carlsen B, Beisland C. Preoperative predictors of pathological tumour stage and prognosis may be used when selecting candidates for intensified treatment in upper tract urothelial carcinoma. Scand J Urol 2021;55:100–7.
[83] Yafi FA, Novara G, Shariat SF, et al. Impact of tumour location versus multifocality in patients with upper tract urothelial carcinoma treated with nephroureterectomy and bladder cuff excision: a homogeneous series without perioperative chemotherapy. BJU Int 2012;110, E7–13.
[84] Chromecki TF, Cha EK, Fajkovic H, et al. The impact of tumor multifocality on outcomes in patients treated with radical nephroureterectomy. Eur Urol 2012;61:245–53.
[85] Fradet V, Mauermann J, Kassouf W, et al. Risk factors for bladder cancer recurrence after nephroureterectomy for upper tract urothelial tumors: results from the Canadian Upper Tract Collaboration. Urol Oncol 2014;32:839–45.
[86] Favaretto RL, Shariat SF, Chade DC, et al. The effect of tumor location on prognosis in patients treated with radical nephroureterectomy at Memorial Sloan-Kettering Cancer Center. Eur Urol 2010;58:574–80.
[87] Ye T, Yang X, Lv P, Liu H, Ye Z. Prognostic value of preoperative hydronephrosis in patients undergoing radical nephroureterectomy for upper tract urinary carcinoma: a systematic review and meta-analysis. Front Oncol 2020;10:600511.
[88] Ma R, Liu Z, Cheng Y, et al. Prognostic value of tumor size in patients with upper tract urothelial carcinoma: a systematic review and meta-analysis. Eur Urol Open Sci 2022;42:19–29.
[89] Colla Ruvolo C, Nocera L, Stolzenbach LF, et al. Tumor size predicts muscle-invasive and non-organ-confined disease in upper tract urothelial carcinoma at radical nephroureterectomy. Eur Urol Focus 2022;8:498–505.
[90] Foerster B, Abufaraj M, Mari A, et al. The performance of tumor size as risk stratification parameter in upper tract urothelial carcinoma (UTUC). Clin Genitourin Cancer 2021;19, 272.e1–7.
[91] Zhang X, Bu R, Liu Z, Wu B, Bai S. Development and validation of a model for predicting intravesical recurrence in organ-confined upper urinary tract urothelial carcinoma patients after radical nephroureterectomy: a retrospective study in one center with long-term follow-up. Pathol Oncol Res 2020;26:1741–8.
[92] Sheu ZL, Huang CP, Chang CH, et al. Tumor distribution affects bladder recurrence but not survival outcome of multifocal upper tract urothelial carcinoma treated with radical nephroureterectomy. Sci Rep 2021;11:19059.
[93] Marchioni M, Primiceri G, Cindolo L, et al. Impact of diagnostic ureteroscopy on intravesical recurrence in patients undergoing radical nephroureterectomy for upper tract urothelial cancer: a systematic review and meta-analysis. BJU Int 2017;120:313–9.
[94] Guo RQ, Hong P, Xiong GY, et al. Impact of ureteroscopy before radical nephroureterectomy for upper tract urothelial carcinomas on oncological outcomes: a meta-analysis. BJU Int 2018;121:184–93.
[95] Liedberg F, Hagberg O, Haggstrom C, et al. Preoperative upper tract invasive diagnostic modalities are associated with intravesical recurrence following surgery for upper tract urothelial carcinoma: a population-based study. PLoS One 2023;18:e0281304.
[96] Parmar K, Hanson M, Mahrous AS, et al. Focused UTUC pathways with a risk-stratified approach to diagnostic ureteroscopy: is it the need of the hour? A retrospective cohort analysis. World J Urol 2024;42:76.
[97] Seisen T, Peyronnet B, Dominguez-Escrig JL, et al. Oncologic outcomes of kidney-sparing surgery versus radical nephroureterectomy for upper tract urothelial carcinoma: a systematic review by the EAU Non–muscle Invasive Bladder Cancer Guidelines Panel. Eur Urol 2016;70:1052–68.
[98] Slusarczyk A, Zapala P, Zapala L, et al. Oncologic outcomes of patients treated with kidney-sparing surgery or radical nephroureterectomy for upper urinary tract urothelial cancer: a population-based study. Urol Oncol 2024;42, 22.e1–11.
[99] Cutress ML, Stewart GD, Wells-Cole S, Phipps S, Thomas BG, Tolley DA. Long-term endoscopic management of upper tract urothelial carcinoma: 20-year single-centre experience. BJU Int 2012;110:1608–17.
[100] Cutress ML, Stewart GD, Zakikhani P, Phipps S, Thomas BG, Tolley DA. Ureteroscopic and percutaneous management of upper tract urothelial carcinoma (UTUC): systematic review. BJU Int 2012;110:614–28.
[101] Cornu JN, Roupret M, Carpentier X, et al. Oncologic control obtained after exclusive flexible ureteroscopic management of upper urinary tract urothelial cell carcinoma. World J Urol 2010;28:151–6.
[102] Villa L, Cloutier J, Letendre J, et al. Early repeated ureteroscopy within 6-8 weeks after a primary endoscopic treatment in patients with upper tract urothelial cell carcinoma: preliminary findings. World J Urol 2016;34:1201–6.
[103] Vemana G, Kim EH, Bhayani SB, Vetter JM, Strope SA. Survival comparison between endoscopic and surgical management for patients with upper tract urothelial cancer: a matched propensity score analysis using Surveillance. Epidemiology and End Results-Medicare data. Urology 2016;95:115–20.
[104] Kawada T, Laukhtina E, Quhal F, et al. Oncologic and safety outcomes for endoscopic surgery versus radical

nephroureterectomy for upper tract urothelial carcinoma: an updated systematic review and meta-analysis. Eur Urol Focus 2023;9:236–40.
[105] Gallioli A, Basile G, Territo A, et al. The importance of second-look ureteroscopy implementation in the conservative management of upper tract urothelial carcinoma. World J Urol 2023;41:2743–9.
[106] Roupret M, Traxer O, Tligui M, et al. Upper urinary tract transitional cell carcinoma: recurrence rate after percutaneous endoscopic resection. Eur Urol 2007;51:709–13.
[107] Steffens J, Humke U, Alloussi S, Ziegler M, Siemer S. Partial nephrectomy and autotransplantation with pyelovesicostomy for renal urothelial carcinoma in solitary kidneys: a clinical update. BJU Int 2007;99:1020–3.
[108] Ou YC, Hu CY, Cheng HL, Yang WH. Long-term outcomes of total ureterectomy with ileal-ureteral substitution treatment for ureteral cancer: a single-center experience. BMC Urol 2018;18:73.
[109] Colin P, Ouzzane A, Pignot G, et al. Comparison of oncological outcomes after segmental ureterectomy or radical nephroureterectomy in urothelial carcinomas of the upper urinary tract: results from a large French multicentre study. BJU Int 2012;110:1134–41.
[110] Abrate A, Sessa F, Sessa M, et al. Segmental ureterectomy versus radical nephroureterectomy in older patients treated for upper tract urothelial carcinoma. Clin Genitourin Cancer 2022;20:381–7.
[111] Silberstein JL, Power NE, Savage C, et al. Renal function and oncologic outcomes of parenchymal sparing ureteral resection versus radical nephroureterectomy for upper tract urothelial carcinoma. J Urol 2012;187:429–34.
[112] Redrow GP, Guo CC, Brausi MA, et al. Upper urinary tract carcinoma in situ: current knowledge, future direction. J Urol 2017;197:287–95.
[113] Giannarini G, Kessler TM, Birkhauser FD, Thalmann GN, Studer UE. Antegrade perfusion with bacillus Calmette-Guerin in patients with non-muscle-invasive urothelial carcinoma of the upper urinary tract: who may benefit? Eur Urol 2011;60:955–60.
[114] Irie A, Iwamura M, Kadowaki K, Ohkawa A, Uchida T, Baba S. Intravesical instillation of bacille Calmette-Guerin for carcinoma in situ of the urothelium involving the upper urinary tract using vesicoureteral reflux created by a double-pigtail catheter. Urology 2002;59:53–7.
[115] Horiguchi H, Yoneyama T, Hatakeyama S, et al. Impact of bacillus Calmette-Guerin therapy of upper urinary tract carcinoma in situ: comparison of oncological outcomes with radical nephroureterectomy. Med Oncol 2018;35:41.
[116] Tomisaki I, Kubo T, Minato A, Fujimoto N. Efficacy and tolerability of bacillus Calmette-Guerin therapy as the first-line therapy for upper urinary tract carcinoma in situ. Cancer Investig 2018;36:152–7.
[117] Yossepowitch O, Lifshitz DA, Dekel Y, et al. Assessment of vesicoureteral reflux in patients with self-retaining ureteral stents: implications for upper urinary tract instillation. J Urol 2005;173:890–3.
[118] Gallioli A, Boissier R, Territo A, et al. Adjuvant single-dose upper urinary tract instillation of mitomycin C After therapeutic ureteroscopy for upper tract urothelial carcinoma: a single-centre prospective non-randomized trial. J Endourol 2020;34:573–80.
[119] Veccia A, Carbonara U, Djaladat H, et al. Robotic vs laparoscopic nephroureterectomy for upper tract urothelial carcinoma: a multicenter propensity-score matched pair "tetrafecta" analysis (ROBUUST collaborative group). J Endourol 2022;36:752–9.
[120] Ji R, He Z, Fang S, et al. Robot-assisted vs. laparoscopic nephroureterectomy for upper urinary tract urothelial carcinoma: a systematic review and meta-analysis based on comparative studies. Front. Oncol 2022;12:964256.
[121] O'Sullivan NJ, Naughton A, Temperley HC, Casey RG. Robotic-assisted versus laparoscopic nephroureterectomy; a systematic review and meta-analysis. BJUI Compass 2023;4:246–55.
[122] Hanna N, Sun M, Trinh QD, et al. Propensity-score-matched comparison of perioperative outcomes between open and laparoscopic nephroureterectomy: a national series. Eur Urol 2012;61:715–21.
[123] Peyronnet B, Seisen T, Dominguez-Escrig JL, et al. Oncological outcomes of laparoscopic nephroureterectomy versus open radical nephroureterectomy for upper tract urothelial carcinoma: an European Association of Urology guidelines systematic review. Eur Urol Focus 2019;5:205–23.
[124] Favaretto RL, Shariat SF, Chade DC, et al. Comparison between laparoscopic and open radical nephroureterectomy in a contemporary group of patients: are recurrence and disease-specific survival associated with surgical technique? Eur Urol 2010;58:645–51.
[125] Walton TJ, Novara G, Matsumoto K, et al. Oncological outcomes after laparoscopic and open radical nephroureterectomy: results from an international cohort. BJU Int 2011;108:406–12.
[126] Ni S, Tao W, Chen Q, et al. Laparoscopic versus open nephroureterectomy for the treatment of upper urinary tract urothelial carcinoma: a systematic review and cumulative analysis of comparative studies. Eur Urol 2012;61:1142–53.
[127] Ariane MM, Colin P, Ouzzane A, et al. Assessment of oncologic control obtained after open versus laparoscopic nephroureterectomy for upper urinary tract urothelial carcinomas (UUT-UCs): results from a large French multicenter collaborative study. Ann Surg Oncol 2012;19:301–8.
[128] Rajan K, Khalifa A, Geraghty R, et al. Oncological efficacy of robotic nephroureterectomy vs. open and laparoscopic nephroureterectomy for suspected non-metastatic UTUC—a systematic review and meta-analysis. Cancers 2023;15:4926.
[129] Simone G, Papalia R, Guaglianone S, et al. Laparoscopic versus open nephroureterectomy: perioperative and oncologic outcomes from a randomised prospective study. Eur Urol 2009;56:520–6.
[130] Roupret M, Smyth G, Irani J, et al. Oncological risk of laparoscopic surgery in urothelial carcinomas. World J Urol 2009;27:81–8.
[131] Ong AM, Bhayani SB, Pavlovich CP. Trocar site recurrence after laparoscopic nephroureterectomy. J Urol 2003;170:1301.
[132] Jeldres C, Lughezzani G, Sun M, et al. Segmental ureterectomy can safely be performed in patients with transitional cell carcinoma of the ureter. J Urol 2010;183:1324–9.
[133] Xylinas E, Rink M, Cha EK, et al. Impact of distal ureter management on oncologic outcomes following radical nephroureterectomy for upper tract urothelial carcinoma. Eur Urol 2014;65:210–7.
[134] Xylinas E, Kluth L, Passoni N, et al. Prediction of intravesical recurrence after radical nephroureterectomy: development of a clinical decision-making tool. Eur Urol 2014;65:650–8.
[135] Phe V, Cussenot O, Bitker MO, Roupret M. Does the surgical technique for management of the distal ureter influence the outcome after nephroureterectomy? BJU Int 2011;108:130–8.
[136] Dominguez-Escrig JL, Peyronnet B, Seisen T, et al. Potential benefit of lymph node dissection during radical nephroureterectomy for upper tract urothelial carcinoma: a systematic review by the European Association of Urology Guidelines Panel on Non–muscle-invasive Bladder Cancer. Eur Urol Focus 2019;5:224–41.
[137] Lughezzani G, Jeldres C, Isbarn H, et al. A critical appraisal of the value of lymph node dissection at nephroureterectomy for upper tract urothelial carcinoma. Urology 2010;75:118–24.
[138] Moschini M, Foerster B, Abufaraj M, et al. Trends of lymphadenectomy in upper tract urothelial carcinoma (UTUC) patients treated with radical nephroureterectomy. World J Urol 2017;35:1541–7.
[139] Xylinas E, Rink M, Margulis V, et al. Prediction of true nodal status in patients with pathological lymph node negative upper tract urothelial carcinoma at radical nephroureterectomy. J Urol 2013;189:468–73.
[140] Bobjer J, Gerdtsson A, Abrahamsson J, et al. Location of retroperitoneal lymph node metastases in upper tract urothelial carcinoma: results from a prospective lymph node mapping study. Eur Urol Open Sci 2023;57:37–44.
[141] Matin SF, Sfakianos JP, Espiritu PN, Coleman JA, Spiess PE. Patterns of lymphatic metastases in upper tract urothelial carcinoma and proposed dissection templates. J Urol 2015;194:1567–74.
[142] Kondo T, Hara I, Takagi T, et al. Template-based lymphadenectomy in urothelial carcinoma of the renal pelvis: a prospective study. Int J Urol 2014;21:453–9.
[143] Kondo T, Hashimoto Y, Kobayashi H, et al. Template-based lymphadenectomy in urothelial carcinoma of the upper urinary tract: impact on patient survival. Int J Urol 2010;17:848–54.
[144] Masson-Lecomte A, Vaillant V, Roumiguie M, et al. Oncological outcomes of distal ureterectomy for high-risk urothelial carcinoma: a multicenter study by the French Bladder Cancer Committee. Cancers 2022;14:5452.

[145] Lima W, Wang Y, Miyamoto H. The impact of routine frozen section analysis during nephroureterectomy or segmental ureterectomy for urothelial carcinoma on final surgical margin status and long-term oncologic outcome. Urol Oncol 2023;41, 357.e1–9.
[146] Villa L, Haddad M, Capitanio U, et al. Which patients with upper tract urothelial carcinoma can be safely treated with flexible ureteroscopy with holmium:YAG laser photoablation? Long-term results from a high volume institution. J Urol 2018;199:66–73.
[147] Baboudjian M, Territo A, Gallioli A, et al. Long-term oncologic outcomes of endoscopic management of high-risk upper tract urothelial carcinoma: the Fundacio Puigvert's experience. J Endourol 2023;37:973–7.
[148] Margulis V, Puligandla M, Trabulsi EJ, et al. Phase II trial of neoadjuvant systemic chemotherapy followed by extirpative surgery in patients with high grade upper tract urothelial carcinoma. J Urol 2020;203:690–8.
[149] Coleman JA, Yip W, Wong NC, et al. Multicenter phase II clinical trial of gemcitabine and cisplatin as neoadjuvant chemotherapy for patients with high-grade upper tract urothelial carcinoma. J Clin Oncol 2023;41:1618–25.
[150] Leow JJ, Chong YL, Chang SL, Valderrama BP, Powles T, Bellmunt J. Neoadjuvant and adjuvant chemotherapy for upper tract urothelial carcinoma: a 2020 systematic review and meta-analysis, and future perspectives on systemic therapy. Eur Urol 2021;79:635–54.
[151] Necchi A, Martini A, Raggi D, et al. A feasibility study of preoperative pembrolizumab before radical nephroureterectomy in patients with high-risk, upper tract urothelial carcinoma: PURE-02. Urol Oncol 2022;40, 10.e1–6.
[152] Seisen T, Colin P, Roupret M. Risk-adapted strategy for the kidney-sparing management of upper tract tumours. Nat Rev Urol 2015;12:155–66.
[153] O'Brien T, Ray E, Singh R, Coker B, Beard R, British Association of Urological Surgeons Section of Oncology. Prevention of bladder tumours after nephroureterectomy for primary upper urinary tract urothelial carcinoma: a prospective, multicentre, randomised clinical trial of a single postoperative intravesical dose of mitomycin C (the ODMIT-C trial). Eur Urol 2011;60:703–10.
[154] Ito A, Shintaku I, Satoh M, et al. Prospective randomized phase II trial of a single early intravesical instillation of pirarubicin (THP) in the prevention of bladder recurrence after nephroureterectomy for upper urinary tract urothelial carcinoma: the THP Monotherapy Study Group trial. J Clin Oncol 2013;31:1422–7.
[155] Hwang EC, Sathianathen NJ, Jung JH, Kim MH, Dahm P, Risk MC. Single-dose intravesical chemotherapy after nephroureterectomy for upper tract urothelial carcinoma. Cochrane Database Syst Rev 2019;2019:CD013160.
[156] Fang D, Li XS, Xiong GY, Yao L, He ZS, Zhou LQ. Prophylactic intravesical chemotherapy to prevent bladder tumors after nephroureterectomy for primary upper urinary tract urothelial carcinomas: a systematic review and meta-analysis. Urol Int 2013;91:291–6.
[157] Harraz AM, El-Shabrawy M, El-Nahas AR, El-Kappany H, Osman Y. Single versus maintenance intravesical chemotherapy for the prevention of bladder recurrence after radical nephroureterectomy for upper tract urothelial carcinoma: a randomized clinical trial. Clin Genitourin Cancer 2019;17, e1108–15.
[158] Birtle AJ, Jones R, Chester J, et al. Improved disease-free survival with adjuvant chemotherapy after nephroureterectomy for upper tract urothelial cancer: final results of the POUT trial. J Clin Oncol 2024;42:1466–71.
[159] Tully KH, Krimphove MJ, Huynh MJ, et al. Differences in survival and impact of adjuvant chemotherapy in patients with variant histology of tumors of the renal pelvis. World J Urol 2020;38:2227–36.
[160] Bajorin DF, Witjes JA, Gschwend JE, et al. Adjuvant nivolumab versus placebo in muscle-invasive urothelial carcinoma. N Engl J Med 2021;384:2102–14.
[161] European Medicines Agency. European Commission approval for Opdivo (nivolumab) as adjuvant treatment for patients with radically resected, high-risk muscle-invasive urothelial carcinoma with tumor cell PD-L1 expression ≥1%. https://www.ema.europa.eu/en/documents/product-information/opdivo-epar-product-information_en.pdf.
[162] Apolo AB, Ballman KV, Sonpavde G, et al. Adjuvant pembrolizumab versus observation in muscle-invasive urothelial carcinoma. N Engl J Med 2025;392:45–55.
[163] Laukhtina E, Sari Motlagh R, Mori K, et al. Chemotherapy is superior to checkpoint inhibitors after radical surgery for urothelial carcinoma: a systematic review and network meta-analysis of oncologic and toxicity outcomes. Crit Rev Oncol Hematol 2022;169:103570.
[164] Hahn AW, Giri S, Pathak R, Bhatt VR, Martin MG. Effect of adjuvant radiotherapy on survival in patients with locoregional urothelial malignancies of the upper urinary tract. Anticancer Res 2016;36:4051–5.
[165] Huang YC, Chang YH, Chiu KH, Shindel AW, Lai CH. Adjuvant radiotherapy for locally advanced upper tract urothelial carcinoma. Sci Rep 2016;6:38175.
[166] Czito B, Zietman A, Kaufman D, Skowronski U, Shipley W. Adjuvant radiotherapy with and without concurrent chemotherapy for locally advanced transitional cell carcinoma of the renal pelvis and ureter. J Urol 2004;172:1271–5.
[167] Iwata T, Kimura S, Abufaraj M, et al. The role of adjuvant radiotherapy after surgery for upper and lower urinary tract urothelial carcinoma: a systematic review. Urol Oncol 2019;37:659–71.
[168] Piontkowski AJ, Corsi N, Morisetty S, et al. Benefit of lymph node dissection in cN+ patients in the treatment of upper tract urothelial carcinoma: analysis of NCDB registry. Urol Oncol 2022;40, 409.e9–17.
[169] Shigeta K, Matsumoto K, Ogihara K, et al. Does neoadjuvant chemotherapy have therapeutic benefit for node-positive upper tract urothelial carcinoma? Results of a multi-center cohort study. Urol Oncol 2022;40, 105.e19–26.
[170] Chakiryan N, Martinez A, Gao L, et al. Optimizing the sequence of chemotherapy for upper tract urothelial carcinoma with clinically positive regional lymph nodes. J Urol 2019;202:76–82.
[171] Powles T, Valderrama BP, Gupta S, et al. Enfortumab vedotin and pembrolizumab in untreated advanced urothelial cancer. N Engl J Med 2024;390:875–88.
[172] Moschini M, Shariat SF, Roupret M, et al. Impact of primary tumor location on survival from the European Organization for the Research and Treatment of Cancer advanced urothelial cancer studies. J Urol 2018;199:1149–57.
[173] van der Heijden MS, Sonpavde G, Powles T, et al. Nivolumab plus gemcitabine-cisplatin in advanced urothelial carcinoma. N Engl J Med 2023;389:1778–89.
[174] De Santis M, Bellmunt J, Mead G, et al. Randomized phase II/III trial assessing gemcitabine/carboplatin and methotrexate/carboplatin/vinblastine in patients with advanced urothelial cancer who are unfit for cisplatin-based chemotherapy: EORTC study 30986. J Clin Oncol 2012;30:191–9.
[175] Powles T, Park SH, Voog E, et al. Avelumab maintenance therapy for advanced or metastatic urothelial carcinoma. N Engl J Med 2020;383:1218–30.
[176] Powles T, Park SH, Voog E, et al. Maintenance avelumab + best supportive care (BSC) versus BSC alone after platinum-based first-line (1L) chemotherapy in advanced urothelial carcinoma (UC): JAVELIN Bladder 100 phase III interim analysis. J Clin Oncol 2020;38(18 Suppl):LBA1.
[177] Vuky J, Balar AV, Castellano D, et al. Long-term outcomes in KEYNOTE-052: phase II study investigating first-line pembrolizumab in cisplatin-ineligible patients with locally advanced or metastatic urothelial cancer. J Clin Oncol 2020;38:2658–66.
[178] Balar AV, Galsky MD, Rosenberg JE, et al. Atezolizumab as first-line treatment in cisplatin-ineligible patients with locally advanced and metastatic urothelial carcinoma: a single-arm, multicentre, phase 2 trial. Lancet 2017;389:67–76.
[179] Bellmunt J, de Wit R, Vaughn DJ, et al. Pembrolizumab as second-line therapy for advanced urothelial carcinoma. N Engl J Med 2017;376:1015–26.
[180] Loriot Y, Matsubara N, Park SH, et al. Erdafitinib or chemotherapy in advanced or metastatic urothelial carcinoma. N Engl J Med 2023;389:1961–71.
[181] De Lorenzis E, Albo G, Longo F, Bebi C, Boeri L, Montanari E. Current knowledge on genomic profiling of upper tract urothelial carcinoma. Genes 2021;12:333.
[182] Yu EY, Petrylak DP, O'Donnell PH, et al. Enfortumab vedotin after PD-1 or PD-L1 inhibitors in cisplatin-ineligible patients with

advanced urothelial carcinoma (EV-201): a multicentre, single-arm, phase 2 trial. Lancet Oncol 2021;22:872–82.
[183] Powles T, Rosenberg JE, Sonpavde GP, et al. Enfortumab vedotin in previously treated advanced urothelial carcinoma. N Engl J Med 2021;384:1125–35.
[184] Seisen T, Jindal T, Karabon P, et al. Efficacy of systemic chemotherapy plus radical nephroureterectomy for metastatic upper tract urothelial carcinoma. Eur Urol 2017;71:714–8.
[185] Moschini M, Xylinas E, Zamboni S, et al. Efficacy of surgery in the primary tumor site for metastatic urothelial cancer: analysis of an international, multicenter, multidisciplinary database. Eur Urol Oncol 2020;3:94–101.
[186] Zhang X, Wang P, Qi K, Qiao Q, Jiang Y. The role of surgery on primary site in metastatic upper urinary tract urothelial carcinoma and a nomogram for predicting the survival of patients with metastatic upper urinary tract urothelial carcinoma. Cancer Med 2021;10:8079–90.
[187] Dong F, Fu H, Shi X, et al. How do organ-specific metastases affect prognosis and surgical treatment for patients with metastatic upper tract urothelial carcinoma: first evidence from population based data. Clin Exp Metastasis 2017;34:467–77.
[188] Nazzani S, Preisser F, Mazzone E, et al. Survival effect of nephroureterectomy in metastatic upper urinary tract urothelial carcinoma. Clin Genitourin Cancer 2019;17, e602–11.
[189] Simsir A, Sarsik B, Cureklibatir I, Sen S, Gunaydin G, Cal C. Prognostic factors for upper urinary tract urothelial carcinomas: stage, grade, and smoking status. Int Urol Nephrol 2011;43:1039–45.
[190] Siefker-Radtke AO, Walsh GL, Pisters LL, et al. Is there a role for surgery in the management of metastatic urothelial cancer? The M. D. Anderson experience. J Urol 2004;171:145–8.
[191] Abe T, Shinohara N, Harabayashi T, et al. Impact of multimodal treatment on survival in patients with metastatic urothelial cancer. Eur Urol 2007;52:1106–13.
[192] Faltas BM, Gennarelli RL, Elkin E, Nguyen DP, Hu J, Tagawa ST. Metastasectomy in older adults with urothelial carcinoma: population-based analysis of use and outcomes. Urol Oncol 2018;36, 9.e11–7.
[193] Xylinas E, Rink M, Margulis V, et al. Multifocal carcinoma in situ of the upper tract is associated with high risk of bladder cancer recurrence. Eur Urol 2012;61:1069–70.
[194] Shigeta K, Kikuchi E, Hagiwara M, et al. The conditional survival with time of intravesical recurrence of upper tract urothelial carcinoma. J Urol 2017;198:1278–85.
[195] Territo A, Gallioli A, Diana P, et al. DNA methylation urine biomarkers test in the diagnosis of upper tract urothelial carcinoma: results from a single-center prospective clinical trial. J Urol 2022;208:570–9.
[196] Zhang ML, Miki Y, Hang JF, et al. A review of upper urinary tract cytology performance before and after the implementation of the Paris system. Cancer Cytopathol 2021;129:264–74.
[197] Chouhan H, Abbass MA, Hrabe JE, et al. Evaluation of urinalysis-based screening for urothelial carcinoma in patients with Lynch syndrome. Dis Colon Rectum 2022;65:40–5.
[198] Myrhoj T, Andersen MB, Bernstein I. Screening for urinary tract cancer with urine cytology in Lynch syndrome and familial colorectal cancer. Fam Cancer 2008;7:303–7.
[199] Mariappan P. Propensity for quality: no longer a tenuous proposition in bladder cancer. Eur Urol 2020;78:60–2.
[200] Konig F, Shariat SF, Karakiewicz PI, Mun DH, Rink M, Pradere B. Quality indicators for the management of high-risk upper tract urothelial carcinoma requiring radical nephroureterectomy. Curr Opin Urol 2021;31:291–6.
[201] Konig F, Grossmann NC, Soria F, et al. Pentafecta for radical nephroureterectomy in patients with high-risk upper tract urothelial carcinoma: a proposal for standardization of quality care metrics. Cancers 2022;14:1781.
[202] Soria F, Pradere B, Hurle R, et al. Radical nephroureterectomy tetrafecta: a proposal reporting surgical strategy quality at surgery. Eur Urol Open Sci 2022;42:1–8.
[203] Sui W, Wallis CJD, Luckenbaugh AN, et al. The impact of hospital volume on short-term and long-term outcomes for patients undergoing radical nephroureterectomy for upper tract urothelial carcinoma. Urology 2021;147:135–42.